



## International Journal of Veterinary Sciences and Animal Husbandry



ISSN: 2456-2912

NAAS Rating (2025): 4.61

VET 2025; SP-10(10): 94-96

© 2025 VET

[www.veterinarypaper.com](http://www.veterinarypaper.com)

Received: 17-07-2025

Accepted: 19-08-2025

**S Mahalakshmi**

Veterinary Dispensary,  
Department of Animal  
Husbandry, Padi, Chennai,  
Tamil Nadu, India

**R Madheswaran**

Department of Veterinary  
Pathology, Veterinary College  
and Research Institute, Tamil  
Nadu Veterinary and Animal  
Sciences University, Udumalpet,  
Tiruppur, Tamil Nadu, India

**M Sasikala**

Department of Veterinary  
Pathology, Veterinary College  
and Research Institute, Tamil  
Nadu Veterinary and Animal  
Sciences University, Udumalpet,  
Tiruppur, Tamil Nadu, India

**D Sumathi**

Department of Veterinary  
Clinical Medicine, Veterinary  
College and Research Institute,  
Tamil Nadu Veterinary and  
Animal Sciences University,  
Namakkal, Tamil Nadu, India

**Corresponding Author:**

**R Madheswaran**

Department of Veterinary  
Pathology, Veterinary College  
and Research Institute, Tamil  
Nadu Veterinary and Animal  
Sciences University, Udumalpet,  
Tiruppur, Tamil Nadu, India

## Occurrence of canine lymphoproliferative disorders in and around Namakkal, Tamil Nadu

**S Mahalakshmi, R Madheswaran, M Sasikala and D Sumathi**

**DOI:** <https://www.doi.org/10.22271/veterinary.2025.v10.i10Sb.2647>

### Abstract

A study was conducted to find out the occurrence of lymphoproliferative disorders (LPDs) in dogs. A total of 66 dogs were diagnosed with LPDs out of 7,246 canine patients brought for treatment. The annual incidence rate of LPDs in dogs recorded as 0.91%. The animal details like breed, age and sex were recorded. Among the breeds, Mongrels were affected more than the pure breeds. The mean age of the dogs affected with LPDs is 4.32 years and it ranged from 2 months to 13.5 years. The LPDs were recorded more in males than females. The dogs affected with skin infections or mite infestations exhibited the signs of localized or generalized lymph node (LN) enlargements. The dogs affected with haemoprotozoan diseases revealed multiple LN enlargements, ecchymotic patches in the ventral abdomen and splenomegaly. The dogs affected with pyogranulomatous lymphadenitis revealed abscessation of entire LN and fever. The dogs affected with lymphoma exhibited multiple LN enlargements, splenomegaly, limb edema, corneal opacities, ascites and respiratory distress. The occurrence of LPDs was influenced by many intrinsic factors and the clinical signs in the dogs varied with the primary conditions.

**Keywords:** LPDs, dogs, age, breed, sex and clinical signs

### Introduction

Lymphatic system is the most vital system in the body, which plays a crucial role in both removal and spread of diseases from one area of the body to another (Mohanty and Wilkinson, 2013) [10]. LNs are the first organ that reacts to inflammation or immune response in the disease conditions. LN enlargement is a common finding in dogs and it is a clinical symptom rather than a definite disease which indicates a number of underlying factors. The common causes of LN enlargements are oedema, reactive hyperplasia, inflammation, infection and neoplasia (Cowell *et al.* 2003; Sapierzynski and Micun, 2009) [2, 12]. LPD is characterized by the enlargement of the LNs as solitary, regional or generalized. It is a heterogenous group of malignant clonal proliferations of lymphocytes. LPD occurs due to impaired immunity caused by immunodeficiency or immunodysregulatory syndromes and usually occurs secondary to bacterial/viral/fungal infections. This paper elucidates the influence of intrinsic factors on the occurrence of LPDs in dogs.

### Materials and Methods

A total of 14,765 dogs were brought to the Veterinary Clinical Complex, Veterinary College and Research Institute, Namakkal from November 2022 to October 2023. Among these dogs, 7,246 cases were presented to the Veterinary Clinical Medicine unit for treatment. Out of these canine patients, 66 dogs were diagnosed with LPDs. The animal details like breed, age and sex were recorded from LPD affected dogs. The clinical signs in LPD affected dogs varied with primary conditions like skin infections or mite infestations, haemoprotozoan diseases, pyogranulomatous lymphadenitis and lymphoma. The enlargement of LNs is the consistent finding among all the LPD affected dogs.

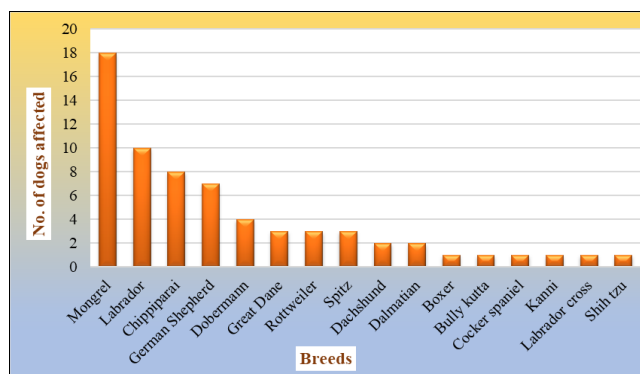
## Results and Discussion

### Incidence

The annual incidence rate of LPD in dogs recorded as 0.91% (66/7246) in this study is more than the earlier observations made by Teske (1994) [13], Atherton and Mason (2022) [1] and Zandvliet (2016) [15]. Teske (1994) [13] reported the annual incidence of canine non-Hodgkin lymphoma is 13 to 24 out of 1,00,000 dogs. Jagielski *et al.* (2002) [4] diagnosed 83% of lymphomas from haematopoietic cancers with high incidence among all tumors in dogs. Kojima *et al.* (2021) [7] observed the most prevalent extranodal lymphoma is gastrointestinal lymphoma which accounts for 5 to 7% of all lymphomas in dogs. Majority of the intestinal lymphomas are from T-cell origin in dogs. More prevalent B-cell lymphomas in humans are diffuse large B-cell lymphoma (DLBCL) and mucosa associated lymphoid tissue (MALT) lymphoma. Atherton and Mason (2022) [1] stated that the most prevalent haematologic malignancies in canines is lymphoma with annual incidence rate of 25 per 1,00,000 dogs.

### Breed

The occurrence of LPDs in various breeds of dogs is presented in Graph 1. Among the breeds, mongrels (n=18) are affected more followed by pure breeds. The breed wise incidence recorded in this study is similar to the findings of Sapierzynski and Micun (2009) [12], Villamil *et al.* (2009) [14] and Jark *et al.* (2020) [5]. These observations are contradicted to the findings of Mylonakis *et al.* (2011) [11] who stated pure breeds are predisposed more than mongrels. Villamil *et al.* (2009) [14] recorded the most common breeds affected with LPDs are Golden retriever, Labrador retriever, German shepherd, Boxer and mixed breeds mainly due to heritable factors. The breeds that are dominant in the population determined the incidence due to environmental and genetic factors.

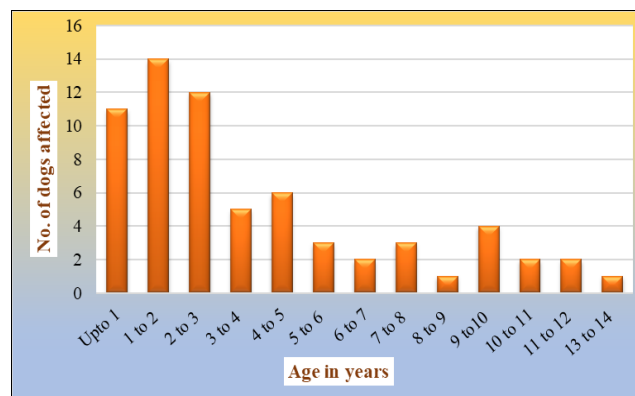


**Graph 1:** Breed wise incidence of lymphoproliferative disorders in dogs

### Age

The occurrence of LPD in different age group of dogs is presented in Graph 2. The mean age of the dogs affected with LPD is 4.32 years and it ranged from 2 months to 13.5 years. The highest incidence was recorded in the age between 1 and 3 years. The age of the dogs affected with LPDs in this study is in agreement with Jark *et al.* (2020) [5] who observed 15.8% of the dogs with less than 5 years of age are affected with LPDs. These observations are different from the findings of Teske (1994) [13], Sapierzynski and Micun (2009) [12] and Atherton and Mason (2022) [1] who recorded the mean age of the dogs affected with LPDs are more than 6.3 years. Teske (1994) [13] observed the mean age of the dogs affected with canine non-Hodgkin lymphoma is ranged from 6.3 to 7.7

years. Zandvliet (2016) [15] recorded the occurrence of lymphoid neoplasia at all age groups but predominantly noticed in the middle aged to older dogs with the incidence of 1.5 cases per 1,00,000 dogs is < 1 year of age to 84 cases per 1,00,000 dogs is > 10 years of age.



**Graph 2:** Age wise incidence of lymphoproliferative disorders in dogs

### Sex

The LPDs observed more in males (n=47) than females (n=19) of this study is agreed to the observations of Jagielski *et al.* (2002) [4], Villamil *et al.* (2009) [14] and Mylonakis *et al.* (2011) [11] and contrary to Jark *et al.* (2020) [5]. Villamil *et al.* (2009) [14] recorded that the male dogs have more sex predisposition to lymphoma than females at and above 4 years of age. Zandvliet (2016) [15] recorded the occurrence of lymphoid neoplasia at all age groups without sex predisposition. The intact females have reduced risk in contrast early sterilization showed increased risk.

### Clinical signs

The dogs with skin infections or mite infestations exhibited localized or generalized LN enlargement depending on local or diffuse skin affections. The haemoprotozoan diseases affected dogs revealed multiple LN enlargements, ecchymotic patches in the ventral abdomen and splenomegaly. The dogs affected with pyogranulomatous lymphadenitis revealed abscessation of entire LN containing purulent material and fever. The dogs affected with lymphoma exhibited multiple LN enlargements, splenomegaly, limb edema, corneal opacities, ascites and respiratory distress.

The clinical signs exhibited by the dogs affected with LPD of this study are similar to the observations of Kol *et al.* (2013) [8], Jung and Jung (2014) [6] and Long *et al.* (2020) [9]. Ghernati *et al.* (2000) [3] reported that the dog with chronic large granular lymphocytic leukemia exhibited diarrhoea and moderate polydipsia. The physical examination of the dog showed moderate splenomegaly without hepatomegaly or LN enlargement.

Kol *et al.* (2013) [8] observed in dogs affected with LPDs exhibited moderately enlarged right mandibular LN of 1.5 cm in diameter and noticeably swollen right inguinal LN of 3.5 cm in diameter. Palpation of abdomen revealed hepatomegaly and abdominal mass. Jung and Jung (2014) [6] reported that the dogs with leukemia revealed abdominal distension, dyspnoea, lethargy, anorexia and weight loss. Physical examination of the dog revealed splenomegaly. Long *et al.* (2020) [9] observed an acute, non-painful facial swelling of right mandibular region which revealed marked lymphadenopathy of submandibular LN on palpation in dogs affected with lymphoid tumors.

## Conclusion

The occurrence of LPDs in dogs was influenced by many intrinsic factors. The LPDs affected dogs showed clinical signs based on the primary conditions like skin infections or mite infestations, haemoprotozoan diseases, pyogranulomatous lymphadenitis and lymphoma. Very few reports are available on the occurrence of LPDs influenced by these factors; hence, the report is presented.

## Acknowledgements

The authors are thankful to the Tamil Nadu Veterinary and Animal Sciences University for providing facility to carry out the research work.

## Conflict of Interest

Not available

## Financial Support

Not available

## References

1. Atherton MJ, Mason NJ. A bitesize introduction to canine hematologic malignancies. *Blood Adv.* 2022;6(13):4073-4084.
2. Cowell RL, Dorsey KE, Meinkoth JH. Lymph node cytology. *Vet Clin North Am Small Anim Pract.* 2003;33(1):47-67.
3. Ghernati I, Corbin A, Chabanne L, Auger C, Magnol JP, Fournel C, *et al.* Canine large granular lymphocyte leukemia and its derived cell line produce infectious retroviral particles. *Vet Pathol.* 2000;37(4):310-317.
4. Jagielski D, Lechowski R, Jagielska MH, Winiarczyk S. A retrospective study of the incidence and prognostic factors of multicentric lymphoma in dogs (1998-2000). *J Vet Med A Physiol Pathol Clin Med.* 2002;49(8):419-424.
5. Jark PC, Fracacio CP, Anai LA, Silva MC, Calazans SG, Senhorello ILS, *et al.* Histopathological and immunophenotypical characterization of canine multicentric lymphoma in Brazil: A study of 203 cases. *Braz Arch Vet Med Anim Sci.* 2020;72(3):787-793.
6. Jung HW, Jung DI. Acute lymphoblastic leukemia and chronic lymphocytic leukemia in dogs. *J Biomed Transl Res.* 2014;15(1):32-35.
7. Kojima K, Chambers JK, Ii T, Nibe K, Mizuno T, Uchida K. Histopathological features and immunophenotyping of canine transmural gastrointestinal lymphoma using full-thickness biopsy samples. *Vet Pathol.* 2021;58(6):1033-1043.
8. Kol A, Christopher MM, Skorupski KA, Tokarz D, Vernau W. B-cell lymphoma with plasmacytoid differentiation, atypical cytoplasmic inclusions and secondary leukemia in a dog. *Vet Clin Pathol.* 2013;42(1):40-46.
9. Long ME, Evans B, Avery AC, Wellman ML. Lymphocytosis and lymphadenopathy in a dog arising from two distinct lymphoid neoplasms. *Vet Clin Pathol.* 2020;49(2):307-311.
10. Mohanty R, Wilkinson A. Utility of fine needle aspiration cytology of lymph nodes. *IOSR J Dent Med Sci.* 2013;8(5):13-18.
11. Mylonakis ME, Borjesson DL, Leontides L, Siarkou VI, Theodorou K, Koutinas AF. Cytologic patterns of lymphadenopathy in canine monocytic ehrlichiosis. *Vet Clin Pathol.* 2011;40(1):78-83.

12. Sapierzynski R, Micun J. Lymphadenomegaly in dogs - Cytological study. *Pol J Vet Sci.* 2009;12(2):263-268.
13. Teske E. Canine malignant lymphoma: A review and comparison with human non-Hodgkin's lymphoma. *Vet Q.* 1994;16(4):209-219.
14. Villamil JA, Henry CJ, Hahn AW, Bryan JN, Tyler JW, Caldwell CW. Hormonal and sex impact on the epidemiology of canine lymphoma. *J Cancer Epidemiol.* 2009;2009:591753.
15. Zandvliet M. Canine lymphoma: A review. *Vet Q.* 2016;36(2):76-104.

## How to Cite This Article

Mahalakshmi S, Madheswaran R, Sasikala M, Sumathi D. Occurrence of canine lymphoproliferative disorders in and around Namakkal, Tamil Nadu. *International Journal of Veterinary Sciences and Animal Husbandry.* 2025; SP-10(10): 94-96.

## Creative Commons (CC) License

This is an open-access journal, and articles are distributed under the terms of the Creative Commons Attribution-Non Commercial-Share Alike 4.0 International (CC BY-NC-SA 4.0) License, which allows others to remix, tweak, and build upon the work non-commercially, as long as appropriate credit is given and the new creations are licensed under the identical terms.