



ISSN: 2456-2912

VET 2023; 8(5): 212-217

© 2023 VET

www.veterinarypaper.com

Received: 11-07-2023

Accepted: 16-08-2023

Rajasekar S

Master Scholar, Department of
Veterinary Surgery and
Radiology, Madras Veterinary
College, Chennai, Tamil Nadu,
India

R Sivashankar

Assistant Professor, Department
of Veterinary Surgery and
Radiology, Madras Veterinary
College, Chennai, Tamil Nadu,
India

H Pushkin Raj

Assistant Professor, Department
of Veterinary Surgery and
Radiology, Madras Veterinary
College, Chennai, Tamil Nadu,
India

K Nagarajan

Assistant Professor, Department
of Veterinary Pathology, Madras
Veterinary College, Chennai-07,
Tamil Nadu, India

Ayyappan S

Professor and Head, Department
of Veterinary Surgery and
Radiology, Madras Veterinary
College, Chennai, Tamil Nadu,
India

Corresponding Author:

R Sivashankar

Assistant Professor, Department
of Veterinary Surgery and
Radiology, Madras Veterinary
College, Chennai, Tamil Nadu,
India

Prevalence and distribution pattern of equine cutaneous wound in and around the Chennai metro city from 2017 to 2020

Rajasekar S, R Sivashankar, H Pushkin Raj, K Nagarajan and Ayyappan S

Abstract

A total of 448 equines were presented to the Large Animal Surgery Unit of Madras Veterinary College Teaching Hospital, Chennai during the period of 2017 to 2020. Of these, 188 (42 per cent) were diagnosed with various forms of wound, 83 (18.5 per cent) were diagnosed lameness, 35 (7.9 per cent) had laminitis, 19 (4.2 per cent) animals were having OA changes, 17 (3.8 per cent) had sprain, 16 (3.6 per cent) had fracture, 16 (3.6) ulcerative keratitis, 15 (3.3 per cent) brought for vaccination, 10 (2.2 per cent) had equine sarcoid, 8 (1.8per cent) underwent castration, 4 (0.9 per cent) had eye worm infestation, 37 (8.2 per cent) had other clinical disorder. Among these 188 (42 per cent) equines with wound, 184 was horses (98 per cent) and 3 were donkeys (1.5 per cent) and 1 was Mule (0.5 per cent) were found wound on one or more of their body parts. The breed wise incidence calculated and was seen high among Kathiyawari horses (n=80, 42.5 per cent) followed by Thoroughbred horses (n=66, 35.1 per cent), pony (n=24, 12.7 per cent), Marwari horses (n=18, 9.5 per cent). The age wise incidence was calculated dividing the animals into four subs set and found to be higher in young animals when compare to old animals. Sex wise incidence was also calculated and higher prevalence found in male when compare to female. The wound was classified based on their type as Lacerated wound (n=54, 28.8 per cent), traumatic wound (n=38, 20.2 per cent), bite wound, (n=28, 14.9 per cent) saddle wound, (n=26, 13.9 per cent) maggot infested wound, (n=22, 11.8 per cent) kick wound (n=12, 6.3 per cent and) surgical wound (n=8, 4.2). In the examined horses wound was frequently observed on body trunk part (n=81, 43 per cent) followed by saddle part (n=26, 13.9 per cent) hoof (n=24 12.8 per cent), fore limb part (n=24, 12.8 per cent), hind limb part (n=23, 12.2 per cent), and head (n=10, 5.3 per cent) respectively.

Keywords: Equine, prevalence, cutaneous wound, trunk, saddle, exuberant granulation tissue

Introduction

Cutaneous wound is defined as damage, break in the continuity of the normal anatomical structure and function of the skin by various etiological factors like cut, laceration, puncture, blunt force and vehicular trauma (Agina & Ihedioha, 2017) ^[1-2]. The epithelial integrity of the skin can be damaged either superficially or in a deep manner extending into the subcutaneous tissue with damage to the surrounding structure like muscles, tendon, vessels, bone and sometimes viscera. In horses depending upon the location type and severity of the injury the working activity of the animal is compromised with various etiological factors like improper transportation, poorly fitted harness and saddle, sharp projection objects in the vehicles during transport, and poor maintenance of paddock have been documented. The objective of this study was to determine the distribution pattern of wound based on age, sex, breed, etiological factors and area of distribution on clinical cases of horses that was brought to the Madras Veterinary College Teaching Hospital Chennai between December 2017 to March 2020.

Materials and Methods

Study Design

The study was retrospective one based on clinical records of diagnosed and conformed case of wound in horses that were brought to Large Animal out Patient surgical Unit at Madras veterinary College Chennai.

The animals were from different sectors like police horses from mounted branch, draft horses, sporting horses, as well as beach riding horses which included in study.

Study Area

The current study was conducted from December 2017 to 2020 March on clinical cases of equids that were brought to Large Animal out Patient Unit Madras Veterinary College Teaching Hospital Chennai- 07. Chennai located on south eastern coast of India having different horses' population which includes Government animals which are employed in army and police forces, beach riding horses, sporting horses, race horses and that are owned by private owners as companion animals.

Statistical Analysis

The data on prevalence of wounds on age, sex, breed, etiology and body distributions of the lesions collected were analyzed statistically by a descriptive statistic and reported in the form of graph and pictures.

Results and Discussion

A total of 448 equines were presented to the Large Animal Surgery Unit of Madras Veterinary College Teaching Hospital, Chennai during the period of 2017 to 2020. Of these, 188 (42 per cent) were diagnosed with various forms of wound, 83 (18.5 per cent) were diagnosed lameness, 35 (7.9 per cent) had laminitis, 19 (4.2 per cent) animals were having OA changes, 17 (3.8 per cent) had sprain, 16 (3.6 per cent) had fracture, 16 (3.6) ulcerative keratitis, 15 (3.3 per cent) brought for vaccination, 10 (2.2 per cent) had equine sarcoid, 8 (1.8per cent) underwent castration, 4 (0.9 per cent) had eye worm infestation, 37 (8.2 per cent) had other clinical disorder. Among these 188 (42 per cent) equines with wound, 184 was horses (98 per cent) and 3 were donkeys (1.5 per cent) and 1 was Mule (0.5 per cent) were found wound on one or more of their body parts. This prevalence figure substantially higher than the previously reported studies which were 7.7 per cent by Knubben *et al.*, (2008) ^[10], 22.6 per cent by Casanova *et al.*, (2014) ^[20], Burden *et al.*, (2010) ^[3] and 7 per cent Mellor *et al.*, (2001) ^[15] but in case of donkeys the prevalence of wound is 1.5 per cent and Mule 0.5 per cent which were lower than previously reported values of 18.2 per cent (Casanova *et al.*, (2014) ^[20]; Burden *et al.*, (2010) ^[3]; Berumen *et al.*, (2009) ^[4] this might be attributed to the less number of donkey and mules reported to the hospital. The overall prevalence of equine wound and species wise prevalence of wound was summarized in Fig. 1 & 2.

The study also revealed that in horses, breed wise incidence of cutaneous wound were found to be high among the Kathiyawari (n=80, 42.5 per cent), followed by thoroughbred (n=66, 35 per cent) and then Marwari (n=18, 9.5 per cent) and Pony (n=24, 12.7 per cent). Perkins *et al.*, (2005) ^[18] observed the same trend on thoroughbred race horses and showed that of the 70 per cent retired due to musculoskeletal injury, 6.7

per cent had wounds or lacerations. Breed wise prevalence of wound was depicted in Fig. 3. The horses with cutaneous wound were distributed among various age groups *viz.* 1 to 5 years (n=56, 29.7%), 6 to 10 years (n=107, 57%), 11 to 15 years (n=13, 7%) and more than 15 years (n=12, 6.3%). The age wise incidence in the present study revealed higher number in the 6-10 years of age and concurred with the finding of Theoret *et al.*, (2015) ^[30] and differed from Owen *et al.*, (2011) ^[17] author reported a higher value in animals with less than 6 months of age group. And the prevalence of wound was more in male 65.4 per cent (123) and 34.6 per cent (65) in females. Age and sex wise prevalence of wound was summarized in Fig. 4 and 5 respectively.

In this study the Lacerative wound was the most frequently observed and higher prevalence of wound type in horses (54, 28.8 per cent) and followed by road trauma (38, 20.2 per cent), bite wound (28, 14.9 per cent), saddle wound (26, 13.9 per cent), Myiasis wound (22, 11.8 per cent), kick wound (12, 6.3 per cent) and surgical wound (8, 4.2 per cent) and it is differing from previous reports of (Tadich *et al.*, (2008) ^[22]; Burden *et al.*, (2010) ^[3]; Upjohn *et al.*, (2012) ^[26]; Casanova *et al.*, (2014) ^[20]. Owen *et al.*, (2011) ^[17] informed that slightly lower per cent of (21.6%) wound that are caused by bite or kick injury when compared to this study. The bite injury was more common in stallion because of effect of stabling of individually housed animals that demonstrated the increased aggressive behavior towards other animals and human as well as introduction of new animals to paddock and increase the incidence of bite and kick, laceration wound by animals and fence around the paddock Knubben *et al.*, (2008) ^[10]. The area of distribution of wound was frequently observed on trunk (n=81, 43 percent) followed by saddle, Hoof, fore limb, hind limb and head which about n= (26), 13.9 per cent, (n=24) 12.8 per cent, (n=24) 12.8 per cent, (n=23) 12.2 per cent, and n= (10) 5.3 per cent of the wound distribution respectively. Owen *et al.*, (2011) ^[17]; Kayode, (2017) ^[12] reported that distal limb was most commonly affected with wound (46 per cent) due to minimal tissue present at cannon region and poorly protected from injury when compared to other area like upper limb and trunk. Agina and Ihedioha, (2017) ^[1-2]; Mespoulhes-Riviere *et al.*, (2008) ^[16] found that distal limbs with wounds were quite common due to race and sport activity, brushing against the wall rough surface, kicking on by other animals, and getting injured by sharp and irregular surfaces from stable and paddock (Shoe nails and pins, broken glass, fence wire, irregular metal object). The saddle wound was the second more highest percentage of wound in this study. This was found to be more than value reported by Abdela *et al.*, (2017) ^[31] (10 5.4 per cent) who described an improper design of saddle and improper riding of horses. Exuberant granulation tissue is a complication that hindered healing of skin wounds on the limbs of horses. The incidence of wound based on the etiology, distribution of wound and different locations was summarized in the Fig. 6, 7 and 8 (a-h).

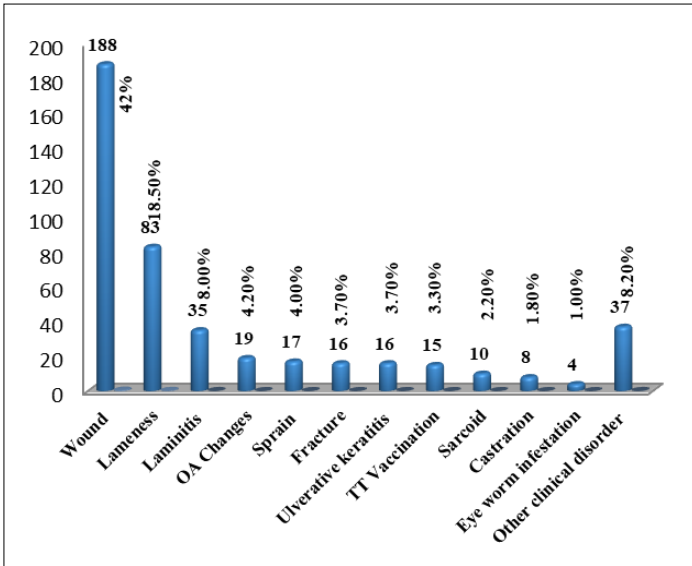


Fig 1: The overall Prevalence of Equine Wound

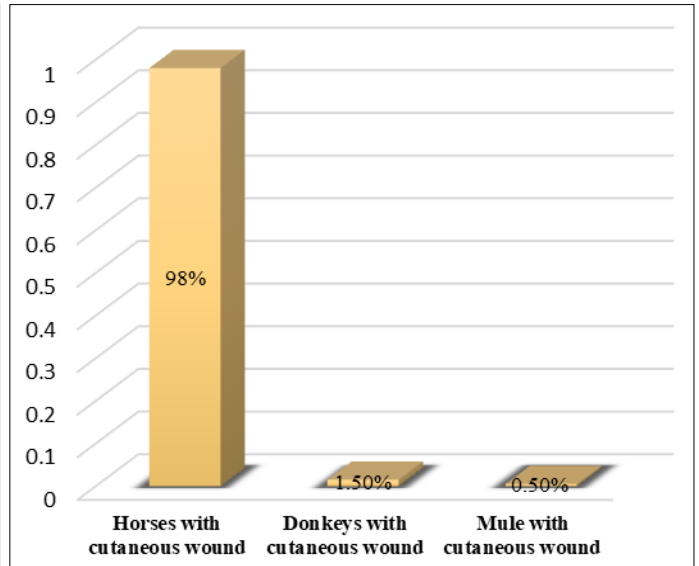


Fig 2: The Species wise Prevalence of Equine Wound

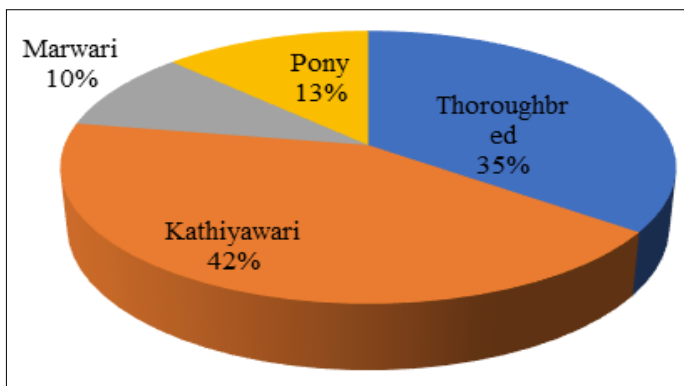


Fig 3: The Breed Wise Prevalence of Wound

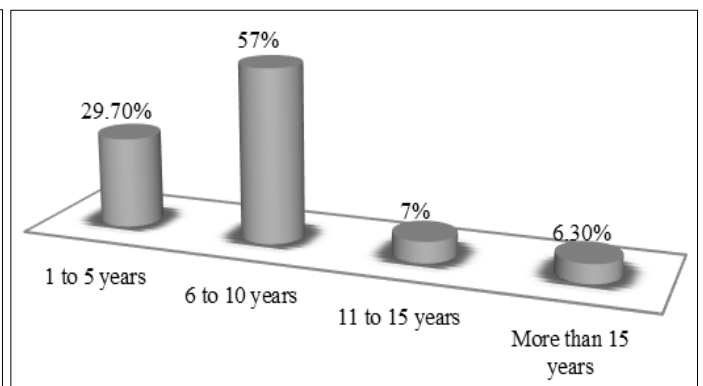


Fig 4: Age Wise Prevalence of Wound

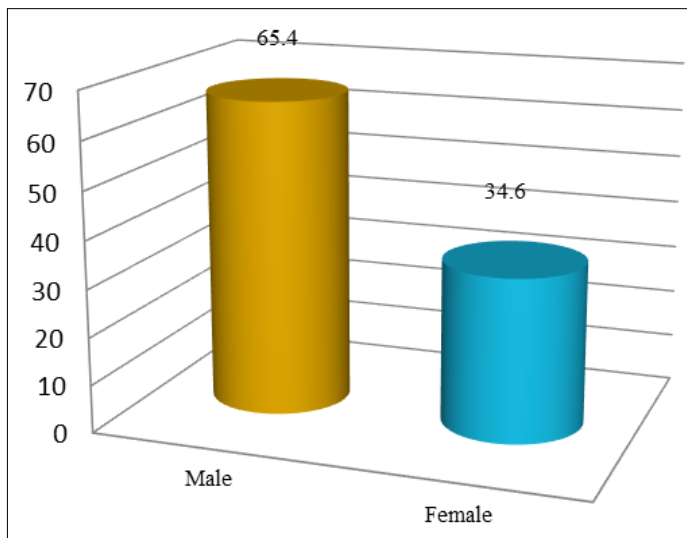


Fig 5: Sex Wise Prevalence of Wound

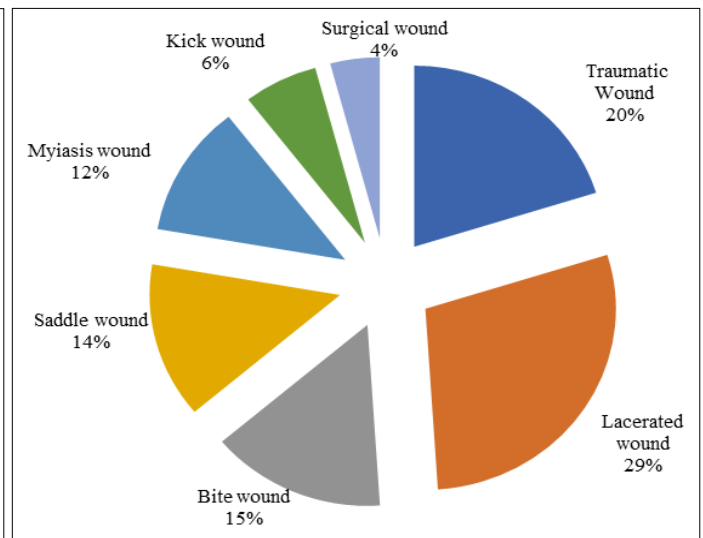


Fig 6: Incidence of Wound based on Etiology

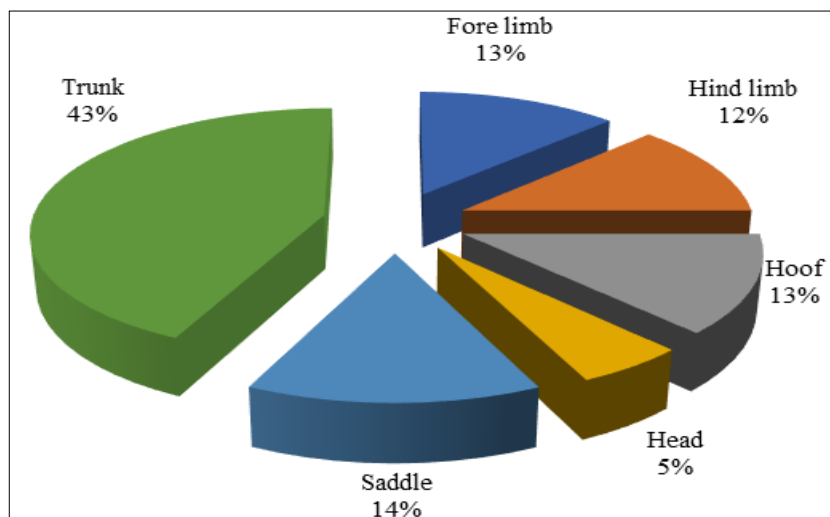


Fig 7: Incidence of Wound based on Distribution of Location









	
Fig 8a: Wound present in forelimb	Fig 8b: Wound present in hind limb
	
Fig 8c: Wound present in saddle region	Fig 8d: Wound present at cannon region
	
Fig 8e: Wound present in body parts point of hip	Fig 8f: Wound present at forelimb cannon region
	
Fig 8g: Wound present at hoof	Fig 8h: Presence of exuberant granulation tissue

Fig 8: Wound Distribution Patterns of Different Locations

Conclusion

Based on the results of this study, it was concluded that there was a relatively higher occurrence of wounds noticed in horses than donkey. Kathiyawari horses had more prevalence of wound than the other breeds, among age group affected 6 to 15 years were prone to wounding and male animal had higher wound occurs when compare to females. Trunk wound and saddle wound were more common followed by distal limb wound. Therefore, proper awareness, education, training on animal handling, and transportation of these horses for equine owner and animal care taker will help to prevent the higher occurrence of wound, and thus improve the health and welfare of the horse's community.

References

1. Agina OA, Ihedioha JI. Occurrence of wounds in Nigerian horses. *Journal of Applied Animal Welfare Science*. 2017;20(4):372-380.
2. Agina OA, Ihedioha JI, Anyanwu MU, Ngwu MI. Clinicopathological and microbiological findings associated with wounds in Nigerian horses. *Comparative Clinical Pathology*. 2017;26(1):181-188.
3. Burden FA, Du Toit N, Hernandez-Gil M, Prado-Ortiz O, Trawford AF. Selected health and management issues facing working donkeys presented for veterinary treatment in rural Mexico: some possible risk factors and potential intervention strategies. *Tropical Animal Health and Production*. 2010;42(4):597-605.
4. Berumen Ramírez VJ. Animal welfare in working Equidae of low-income owners in Aguascalientes. *Universidad de Aguascalientes*. Aguascalientes, Mexico; c2009.
5. Coomer RP. Management of traumatic wounds in horses; c2008. p. 151-157.
6. Dubuc V, Lepault É, Theoret CL. Endothelial cell hypertrophy is associated with microvascular occlusion in horse wounds. *Canadian journal of veterinary research*. 2006;70(3):206.
7. De Souza MV, De Oliveira Pinto J, Varaschin MS, Lopes JDCM, De Oliveira Silva T, Coelho PGB. Macroscopic and histomorphometric evaluation of different healing stages of skin wounds in horses treated with leukocyte-poor platelet-rich plasma. *Acta Veterinaria Brasilica*. 2017;11(2):111-123.
8. Hendrickson D, Virgin J. Factors that affect equine wound repair. *Veterinary Clinics: Equine Practice*. 2005;21(1):33-44.
9. Houpt KA, Lieb S. Horse Handling and Transport 16. *Livestock Handling and Transport*; c2000, 297.
10. Knubben JM, Fürst A, Gygax L, Stauffacher M. Bite and kick injuries in horses: Prevalence, risk factors and prevention. *Equine Veterinary Journal*. 2008;40(3):219-223.
11. Knottenbelt DC. *Pascoe's Principles and Practice of Equine Dermatology E-Book*. Elsevier Health Sciences; c2009.
12. Kayode OA. Epidemiological study on wound distribution pattern in horses presented at two veterinary clinics in south-west, Nigeria between 2007-2010. *Journal of Dairy, Veterinary & Animal Research*. 2017;5(4):00148
13. Lepault É, Céleste C, Doré M, Martineau D, Theoret CL. Comparative study on microvascular occlusion and apoptosis in body and limb wounds in the horse. *Wound repair and regeneration*. 2005;13(5):520-529.
14. Miragliotta V, Pirone A, Donadio E, Abramo F, Ricciardi MP, Theoret CL. Osteopontin expression in healing wounds of horses and in human keloids. *Equine veterinary journal*. 2016;48(1):72-77.
15. Mellor DJ, Reid SWJ, Love S, Walker R, Gettinby G. Sentinel practice-based survey of the management and health of horses in northern Britain. *Veterinary Record*. 2001;149(14):417-423.
16. Mespoullhès-Rivière C, Martens A, Bogaert L, Wilderjans H. Factors affecting outcome of extensor tendon lacerations in the distal limb of horses. *Veterinary and Comparative Orthopaedics and Traumatology*. 2008;21(04):358-364.
17. Owen KR, Singer ER, Clegg PD, Ireland JL, Pinchbeck GL. Identification of risk factors for traumatic injury in the general horse population of north-west England, Midlands and north Wales. *Equine Veterinary Journal*. 2012;44(2):143-148.
18. Perkins NR, Reid SWJ, Morris RS. Profiling the New Zealand Thoroughbred racing industry. 2. Conditions interfering with training and racing. *New Zealand Veterinary Journal*. 2005;53(1):69-76.
19. Schwean K. The welfare of horses: Review of recent literature; c2005. Retrieved from <http://www.prairieswine.com/wp-content/uploads/2012/02/horses.pdf>.
20. Sanchez-Casanova RE, Masri-Daba M, Alonso-Diaz MA, Mendez-Bernal A, Hernandez-Gil M, Fernando-Martinez JA. Prevalence of cutaneous pathological conditions and factors associated with the presence of skin wounds in working equids in tropical regions of Veracruz, Mexico. *Tropical animal health and production*. 2014;46(3):555-561.
21. Theoret C. Physiology of wound healing. *Equine wound management*; c2016. p. 1-13.
22. Tadich T, Escobar A, Pearson RA. Husbandry and welfare aspects of urban draught horses in the south of Chile. *Archivos de medicina veterinaria*. 2008;40(3):267-273.
23. Theoret CL, Barber SM, Moyana TN, Gordon JR. Expression of transforming growth factor β 1, β 3, and basic fibroblast growth factor in full-thickness skin wounds of equine limbs and thorax. *Veterinary Surgery*. 2001;30(3):269-277.
24. Theoret CL, Bolwell CF, Riley CB. A cross-sectional survey on wounds in horses in New Zealand. *New Zealand Veterinary Journal*. 2016;64(2):90-94.
25. Equine USDA. Part I: baseline reference of equine health and management. USDA: APHIS: VS, CEAH. Fort Collins, CO, 2005;451:1006.
26. Upjohn MM, Shipton K, Pfeiffer DU, Leretholi T, Attwood G, Verheyen KLP. Cross-sectional survey of owner knowledge and husbandry practices, tack and health issues affecting working horses in Lesotho. *Equine Veterinary Journal*. 2012;44(3):310-318.
27. Wilmink JM, Stolk PT, Van Weeren PR, Barneveld A. Differences in second-intention wound healing between horses and ponies: macroscopic aspects. *Equine Veterinary Journal*. 1999;31(1):53-60.
28. Wilmink JM, Van Weeren PR, Stolk PT, Van Mil FN, Barneveld A. Differences in second-intention wound healing between horses and ponies: histological aspects. *Equine Veterinary Journal*. 1999;31(1):61-67.
29. Van Hecke LL, Hermans K, Haspelslagh M, Chiers K, Pint E, Boyen F, *et al*. A quantitative swab is a good non-

- invasive alternative to a quantitative biopsy for quantifying bacterial load in wounds healing by second intention in horses. *The Veterinary Journal*. 2017;225:63-68.
30. Théoret-Gosselin R, Hamel S, Côté SD. The role of maternal behavior and offspring development in the survival of mountain goat kids. *Oecologia*. 2015 May;178:175-86.
31. Tiimob BJ, Mwinyelle G, Abdela W, Samuel T, Jeelani S, Rangari VK. Nanoengineered eggshell–silver tailored copolyester polymer blend film with antimicrobial properties. *Journal of agricultural and food chemistry*. 2017 Mar 8;65(9):1967-76.