



ISSN: 2456-2912
VET 2022; 7(2): 28-30
© 2022 VET
www.veterinarypaper.com
Received: 09-02-2022
Accepted: 12-03-2022

Juripriya Brahma
Junior Scientist, Department of
Veterinary Clinical Medicine,
Livestock Research Station,
Assam Agricultural University,
Mandira, Assam, India

Mihir Sarma
Junior Scientist, Department of
Poultry Science, Livestock
Research Station, Assam
Agricultural University,
Mandira, Assam, India

Prasanta Boro
Junior Scientist, Department of
Livestock Production and
Management, Livestock
Research Station, Assam
Agricultural University,
Mandira, Assam, India

HK Bhattacharyya
Chief Scientist, Department of
Animal reproduction,
Gynecology and Obstetrics,
Assam Agricultural University,
Mandira, Assam, India

BC Baishya
Assistant Professor, Department
of Veterinary Clinical Medicine,
Teaching Veterinary Clinical
Complex, College of Veterinary
Science, Assam Agricultural
University, Khanapara, Assam,
India

J Saharia
Professor and Head, Department
of Livestock Production and
Management, College of
Veterinary Science, Assam
Agricultural University,
Khanapara, Assam, India

Corresponding Author
Juripriya Brahma
Junior Scientist, Department of
Veterinary Clinical Medicine,
Livestock Research Station,
Assam Agricultural University,
Mandira, Assam, India

The normal electrocardiographic studies in healthy Assam hill goats

Juripriya Brahma, Mihir Sarma, Prasanta Boro, HK Bhattacharyya, BC Baishya and J Saharia

DOI: <https://doi.org/10.22271/veterinary.2022.v7.i2a.411>

Abstract

The aim of this study was to determine the normal electrocardiographic (ECG) values for standard lead II in Assam hill goats. The mean heart rate in the goats studied was 103.65 ± 4.91 beats/minute and ranged between 90 and 130 bpm. The P voltage in lead II was oriented in the positive direction. No negative P wave was found. The lead II P wave amplitude was 0.1 ± 0.009 mV and P wave duration was 0.03 ± 0.001 s. The T wave amplitude and duration were $0.13 \text{mV} \pm 0.010$ and $0.04 \text{s} \pm 0.001$. The QRS complex amplitude and duration were 0.32 ± 0.02 mV and 0.04 ± 0.001 s. The duration of PR interval, ST interval, and QT in lead II recorded are 0.07 ± 0.003 , $0.14 \text{s} \pm 0.003$, and 0.22 ± 0.001 s respectively.

Keywords: ECG, Assam hill goat, heart rate, amplitude, duration

1. Introduction

Electrocardiography in clinical practice is the recording of electrical activity generated by the heart on body surface. This is associated with depolarization and repolarization of the myocardium that occurs in a definite pattern (Pourjafar *et al.*, 2012 and Radostits *et al.*, 2007) [14, 15]. Goat has advantages of small body size, easy availability and cheapness which make it more preferable over other ruminants for biological research (Mohan *et al.*, 2005) [12]. Electrocardiography is a non-invasive, inexpensive technique that yields useful information arrhythmias, diagnosing conduction abnormalities and it also is a valuable aid in prognostic and therapeutic considerations (Fregin., 1985) [6]. It is the test of choice to initially evaluate cardiac problems associated with the initiation and conduction of waves of depolarization. The sophistication of cardiac diagnosis has improved remarkably over the last few decades (Houghton and Gray, 1997) [8] and the study of electrocardiogram (ECG) pattern is very useful in the detection of abnormal heart conditions (Venkateshwarlu *et al.*, 1977) [20]. However, most of the literature on the electrocardiogram among domestic animals is related to dogs and horses (Mohan *et al.*, 2005) [12] and the ECG has been rarely applied in caprine medicine (Smith & Sherman., 2009) [17]. Quite few studies describe the process of ventricular activation (Hamlin RL *et al.*, 1984) and variability of QRS complex (Szabuniewicz M and Clark DR., 1967) [18] or goats under experimental conditions (Itabisashi T., 1977) [9] or values for few leads only (Upadhyay RC and Sud SC., 1977) [19]. The heart of the goat is reported to vary in size and form according to the breed (Dyce *et al.*, 1987) [4] and this variation is expected to be reflected in the ECG. Electrocardiography is most useful and widely used investigation for diagnosis of cardiac arrhythmia in animal. Therefore, research work on normal electrocardiographic studies in healthy Assam hill goats were undertaken. The purpose of the study was to establish normal reference ECG values of healthy Assam hill goats (limb lead II).

2. Materials and Methods

The present study was performed at Livestock Research Station, AAU, Mandira and Goat Research Station, AAU, Byrnihat for a period of six months (January 2021 to June 2021) on healthy Assam hill goats. A total of 20 healthy Assam hill goats of both sexes and age group of 1 to 3 years were selected for the study. The animals were examined prior to ECG recording and were proved to be clinically healthy.

None of the goat used in this study had any clinical signs of systemic diseases, respiratory, enteric, heart diseases and anemia etc. The standard bipolar limb leads (I, II, III) were recorded with the goats in a standing position, without sedation using alligator clip electrodes with a little cardiac gel applied just below the elbow and stifle joints of the forelimb and hind limb (Figure 1 & 2). ECG recordings were made during morning hour using 12-lead standard ECG recorder (Model-Cardiart GenX3, manufactured by BPL, India). The paper speed was set to 25 mm/s with the sensitivity of the machine was adjusted at 1 mv=10mm. Heart rate was calculated according to the R-R interval in lead-II. The amplitude and duration of P waves, QRS complexes and T waves were analysed in lead II. The duration of PR interval, ST interval and QT interval in lead II were recorded.



Fig 2: Performing an electrocardiogram (ECG) on goat at Goat Research Station, AAU, Byrnihat



Fig 1: Performing an electrocardiogram (ECG) on goat at LRS, AAU, Mandira

3. Result

The mean heart rate of Assam hill goats studied was 103.65±4.91 beat per minute and ranged between 90 and 130 bpm. The amplitude of P wave, QRS and T waves recorded was 0.1 mV±0.009, 0.32mV±0.02 and 0.13 mV±0.010. The P and T voltage in lead II was oriented in the positive direction and lower QRS amplitude was observed. The duration of P wave, PR interval, QRS, ST interval, T wave and QT in lead II recorded are 0.03s±0.001, 0.07±0.003, 0.04s±0.001, 0.14s±0.003, 0.04s±0.001 and 0.22s±0.001 respectively. The normal ECG of healthy Assam hill goats are represented in Table 1 and Figure 2.

Table 1: Mean value of heart rate, p wave amplitude, P wave duration, T wave amplitude, T wave duration, P-R interval duration, QRS duration, QRS Amplitude, ST duration, QT duration

Parameters	Mean±SE
Heart Rate	103.65±4.91
p wave amplitude	0.1 mV±0.009
P wave duration	0.03s±0.001
T wave amplitude	0.13 mV±0.010
T wave duration	0.04s±0.001
P-R interval duration	0.07±0.003
QRS duration	0.04s±0.001
QRS Amplitude	0.32mV±0.02
ST duration	0.14s±0.003
QT duration	0.22s±0.001

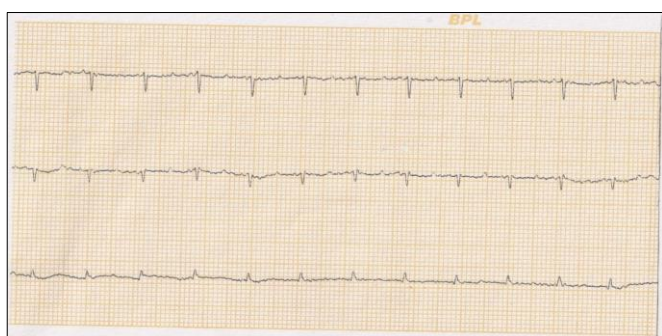


Fig 2: Normal electrocardiogram of Assam hill goat

4. Discussion

The normal heart rate of Assam hill goats aged between 1-3 years old recorded in the study was 90 and 130 bpm with a mean value 103.65±4.91 bpm. Heart rate of Black Bengal goats aged between 1-3 years was 68-150 bpm with an average 101±2.6 bpm reported by (Jafrin Ara Ahmed and Sagar Sanyal, 2008) [10]. Variations in the heart rate may be expected with difference in age and size of animals and in case of breed variation may be due to differences in the size and form of heart. This variation is expected to be reflected in

ECG parameters (Andrassy *et al.*, 2005) [2]. The P voltage in lead II was oriented in the positive direction and the mean value was almost similar to those obtained by (Mohan *et al.*, 2005) [12] but higher than observed in the studies for Black Bengal goats (Ahmed & Sanyal, 2008) [1], Kagani goats (Raina *et al.*, 2008) [16], cross-bred goats (Kant *et al.*, 2010) [11] and Markhoz goats (Fakour *et al.*, 2013) [5]. This might be due to breed difference in the goats studied. No negative P wave was found. The QRS voltage were lower than those reported for Horse and Dogs (Breazile GE, 1971) [3]. The low amplitude QRS deflection might be due to high degree of synchronized ventricular depolarization. The T wave was observed positive for lead II, amplitude was similar to the mean values presented by (Ahmed & Sanyal 2008 [1] and Fakour *et al.*, 2013) [5], for Black Bengal and Markhoz goats, and lower than the values found by (Kant *et al.*, 2010) [11] for cross-bred goats and higher than the mean values found by (Mohan *et al.*, 2005 and Raina *et al.*, 2008) [12, 16] for Jamunapari and Kagani goats, respectively. Wave variability (form and amplitude) of the ECG may be attributed determining factor like difference in the topographic anatomy of the heart within thorax, position of heart in relation to the limbs and mechanism of activation of ventricles as reported

by (Szabuniewicz M and Clark DR., 1967)^[18]. The P duration for Assam hill goats in line with (Kant *et al.*, 2010 and Fakour *et al.*, 2013)^[11, 5]. Differences of P values might be due to breed difference in the goats (Mohan *et al.*, 2005)^[12]. The lead II PR interval value were similar with the results of (Mohan *et al.*, 2005)^[12]. The mean values found for PR interval were lower than the results reported by (Ahmed & Sanyal., 2008, Raina *et al.*, 2008, Kant *et al.*, 2010 and Fakour *et al.*, 2013)^[1, 16, 11, 5] and higher than the results reported by (Matos *et al.*, 1994)^[13] for kids. The lead II QT interval was similar to the mean values found by (Mohan *et al.*, 2005 and Fakour *et al.*, 2013)^[12, 5], and higher than the results reported by (Raina *et al.*, 2008 and Kant *et al.*, 2010)^[16, 11], and lower than the results reported by (Matos *et al.*, 1994)^[13]. The lead II ST segment values were found similar with (Mohan *et al.*, 2005)^[12].

5. Acknowledgments

The authors are thankful to the Directorate of Research (Veterinary), AAU, Khanapara for providing the necessary facilities for conducting the research work. The authors thank all scientists of LRS, AAU, Mandira and Goat Research Station, AAU, Byrnihat for providing the technical assistance required for the study. The authors are also thankful for the casual labourers engaged in LRS, AAU, Mandira and Goat Research Station, AAU, Byrnihat for their keen interest in handling the animals.

6. Conclusion

The research study on normal Electrocardiographic studies in healthy Assam hill goats carried out in Livestock Research Station, AAU, Mandira and Goat Research Station, AAU, Byrnihat provides baseline information regarding normal ECG parameters (Lead II) in Assam hill goats, further the study provides reference values of normal Electrocardiographic parameters (Lead II) of Assam hill goats for clinicians and researchers.

7. References

- Ahmed JA, Sanyal S. Electrocardiographic studies in Garol Sheep and black Bengal goats. *Res. J Cardiol.* 2008;1(1):1-8.
- Andrassy G, Szabo A, Dunai A, Bengtson JR, Leavy D. Heart rate correction of the QT interval during exercise. *Cardiovascular Hungarica.* 2005;35(5):17-20.
- Breazile JE. *Textbook of Veterinary Physiology.* Lea and Febiger, Philadelphia, 1971, 241-251.
- Dyce KM, Sack WO, Wensing CJG. *Text book of Veterinary Anatomy.* Saunders, Philadelphia; c1987. p. 629.
- Fakour S, Mokhber Dezfuli MR, Nadalian MG, Rezakhani A, Lotfollah ZS. Electrocardiographic parameters of Markhoz goat using base apex lead and six standard limb leads. *Iran. J Vet. Res.* 2013;14(3):241-244.
- Fregin FG. Electrocardiography. *Vet. Clin. North Am., Equine Pract.* 1985;1:419-432.
- Hamlin RL, Glower DD, Jr Pimmel RL. Genesis of QRS in the ruminant: Graphic stimulation. *Am J Vet Res.* 1984;45:938-941.
- Houghton AR, Gray D. *Making Sense of the ECG: A Hands-on Guide.* Arnold, a Member of the Hodder Headline Group, London; c1997. p. 77-96.
- Itabisashi T. Electrocardiographic observation on goats with urea poisoning and consideration on the main cause of death. *Natl Inst Anim Health Q (Tokyo).* 1977 Jan 1;17(4):151-62.
- Jafrin Ara Ahmed, Sagar Sanyal. Electrocardiographic Studies in Garol Sheep and Black Bengal Goats. *Research Journal of Cardiology.* 2008;1(1):1-8.
- Kant V, Srivastava AK, Verma PK, Raina R, Pankaj NK. Alterations in electrocardiographic parameters after subacute exposure of fluoride and ameliorative action of aluminium sulphate in goats. *Biol. Trace Elem. Res.* 2010 May;134(2):188-94.
- Mohan NH, Niyogi D, Singh HN. Analysis of normal electrocardiograms of Jamunapari goats. *J Vet. Sci.* 2005 Dec 1;6(4):295-8.
- Montes AM, Bernal LJ, Bayon A, Fernandez-Del Palacio MJ, Sotillo J, Ayala I, *et al.* A Study of ECG in Goats. *Proceedings. 18th World Bariatrics Congress Italy.* 1994;18:1201-1024.
- Pourjafar M, Badie K, Chalmeh A. Evaluation of ST-segment duration and morphology of standard base apex lead electrocardiograms in different age groups of apparently healthy Holstein cattle. *Journal of the Faculty of Veterinary Medicine Istanbul University.* 2012;38(1):51-8.
- Radostits OM, Gay C, Hinchcliff KW, Constable PD. Diseases of the cardiovascular system. In: *Veterinary Medicine: A Textbook of the Disease of Cattle, Horses, Sheep, Pigs and Goats.* Saunders, London. 2007;10:2045-50.
- Raina R, Verma PK, Pankaj NK, Prawez S, Srivastava AK. Effects of tramadol on electrocardiogram, mean electrical axis and respiration in kagani goats (*Capra hircus*). *Iran. J. Pharmacol. Ther.* 2008 Jul;7:157-60.
- Smith MC, Sherman DM. *Goat Medicine.* Wiley-Blackwell, Iowa; c2009. p. 319-338.
- Szabuniewicz M, Clark DR. Analysis of the electrocardiograms of 100 normal goats. *Am J Vet Res.* 1967 Mar;28(123):511-516.
- Upadhyay RC, Sud SC. Electrocardiogram of the goat. *Indian J Exp Biol.* 1977 May;15(5):359-62.
- Venkateshwarlu K, Syaam Sunder N, Choudhuri PC. Electrocardiographic observations in healthy dogs. *Indian Vet. J.* 1977;74(2):155-158.