



ISSN: 2456-2912  
VET 2019; 4(1): 29-31  
© 2019 VET  
www.veterinarypaper.com  
Received: 19-11-2018  
Accepted: 21-12-2018

**Gyan Singh**

Assistant Professor, Department of  
Veterinary Clinical and Complex,  
College of Veterinary Sciences, Lala  
Lajpat Rai University of Veterinary  
and Animal Sciences, Hisar, Haryana,  
India

**Ravi Dutt**

Assistant Professor, Department of  
Veterinary Gynaecology and  
Obstetrics, College of Veterinary  
Sciences, Lala Lajpat Rai University  
of Veterinary and Animal Sciences,  
Hisar, Haryana, India

**Jasmer Dalal**

Ph.D. Scholar, Department of  
Veterinary Gynaecology and  
Obstetrics, College of Veterinary  
Sciences, Lala Lajpat Rai University  
of Veterinary and Animal Sciences,  
Hisar

**Arjun V**

M.V.Sc Scholar, Department of  
Veterinary Gynaecology and  
Obstetrics, College of Veterinary  
Sciences, Lala Lajpat Rai University  
of Veterinary and Animal Sciences,  
Hisar

**Vinay Yadav**

M.V.Sc Scholar, Department of  
Veterinary Gynaecology and  
Obstetrics, College of Veterinary  
Sciences, Lala Lajpat Rai University  
of Veterinary and Animal Sciences,  
Hisar

**BL Jangir**

Assistant Professor, Department of  
Veterinary Pathology, College of  
Veterinary Sciences, Lala Lajpat Rai  
University of Veterinary and Animal  
Sciences, Hisar

**Correspondence**

**Ravi Dutt**

Assistant Professor, Department of  
Veterinary Gynaecology and  
Obstetrics, College of Veterinary  
Sciences, Lala Lajpat Rai  
University of Veterinary and  
Animal Sciences, Hisar, Haryana,  
India

## Per-vaginal delivery of a lipomatous fetus accompanying with ascites in a Murrah buffalo

Gyan Singh, Ravi Dutt, Jasmer Dalal, Arjun V, Vinay Yadav and BL Jangir

### Abstract

An eight years old pluriparous Murrah buffalo at full term of gestation suffering from dystocia was presented to Veterinary Clinical Complex of the university. Per-vaginal examination of the dam revealed both hind limbs of the fetus extended in the birth canal, fetal ascites and large mass in the abdomen. Ascitic fluid and lipomatous mass were removed manually after puncturing the fetal abdomen and the deformed fetus was delivered per vaginally by gentle traction.

**Keywords:** Ascites, buffalo, dystocia, lipomatous fetus

### Introduction

Congenital malformations (due to genetic causes) represent a hidden danger for animal production and reproduction, above all when genetic selection is undertaken for production improvements and are responsible for economic losses either because they reduce the productivity of the farm, or because their spread in the population would decrease the total productivity of that species/breed [1]. Congenital abnormalities are present at birth and dropsy of peritoneum i.e. fetal ascites is a common accompaniment of infectious disease of the fetus and of developmental defects such as achondroplasia [2]. Neoplasms of adipose tissue rarely occur in adult cattle and are usually single and localized in abdominal cavity. Incidence of subcutaneous lipomas appears to be quite low and usually reported in adult cattle [3]. Congenital neoplasms are uncommon in animals, especially in bovids [4]. Genetical, environmental factors, carcinogenic drugs or miscellaneous toxic substances are among the probable causes of this neoplasm [5]. Little information is available on congenital lipomas in calves [6]. The Present case report deals with oversized lipomatous fetus with ascites in a Murrah buffalo and its successful management.

### Case report

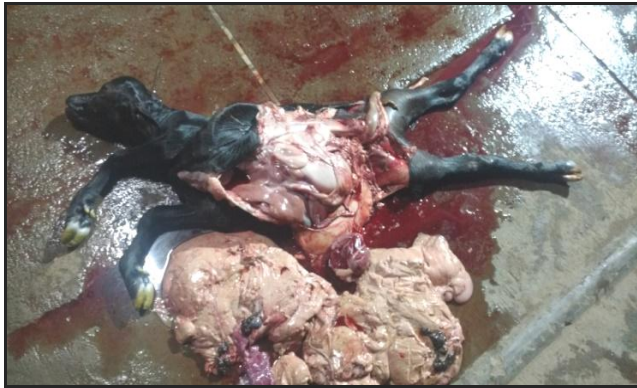Eight years old pluriparous Murrah buffalo (OPD No. E-10-4514 dated 27.10.2018) suffering from dystocia was brought to the Veterinary Clinical Complex of LUVAS, Hisar. Animal was dull, depressed and exhausted due to constant straining. Epidural anaesthesia was given with 5ml of 2% lignocaine hydrochloride. Per-vaginal examination revealed dead fetus in posterior presentation, dorso-sacral position with hind limb extended in birth canal. Lump of round mass was palpated in distended fetal abdominal cavity filled with excessive fluid. The abdominal cavity of fetus was punctured by chiselled long eye hook to evacuate the ascitic fluid and to remove the round mass. After removal of round mass, fetus was delivered by applying gentle traction on fetal hind limbs with the help of snares (Fig.1). The placenta was expelled within fifteen minutes after removal of the fetus. Histopathological examination of fetal abdominal masses revealed lipomatous in origin. The kidneys of the fetus were embedded in lipomatous mass.

The dam was administered with Inj. Metrogyl® (JB Chemicals; Metronidazole 3000mg/600 ml) IV, Inj. Cefwell forte® (Cefoperazone plus sulbactam; Macwell pharma) 4.5g IM, Inj. Megludyne® (Flunixin meglumine; Virbac Animal Health India Pvt Ltd.) 1000 mg IM, Inj. Avilin® (Pheniramine maleate; MSD Animal Health) 10 ml IM, Inj. Ergovet® (Methyl-ergometrine maleate; Carus Laboratories Pvt. Ltd.) 10 IM, Inj. Mifex® (Calcium-magnesium-boro-gluconate; Novartis India Limited)

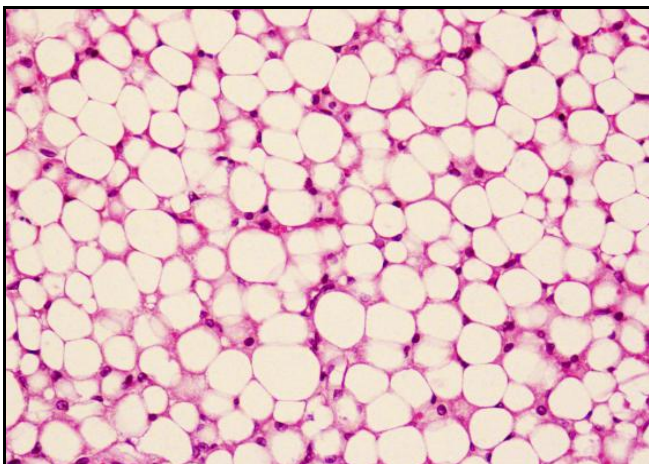


450 ml slow IV, Inj. Dextrose Normal Saline (Dextrose 5%; Fresenius Kabi) 5 litres IV and Inj. Evatocin® (Oxytocin; Neon laboratories) 10ml in 1 liter of normal saline IV.

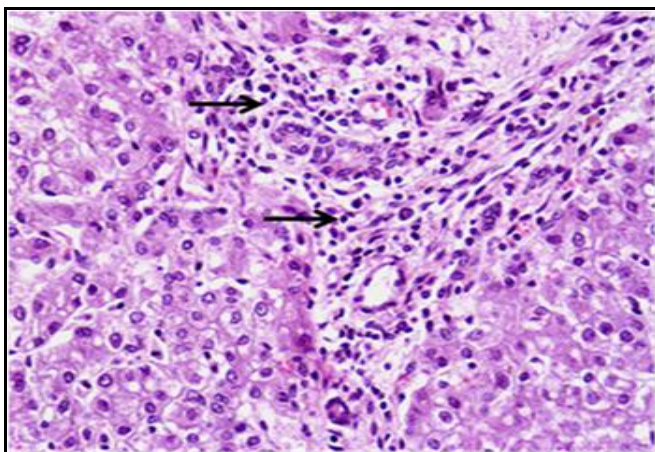
Histopathological studies revealed lipomatous mass showing adipose cells with eccentrically placed nuclei (Fig. 2). The section of liver showed vacuolar degenerative changes in hepatocytes and infiltration of mononuclear cells mainly lymphocytes (arrows) in periportal areas (Fig. 3). The fetal kidneys showed cellular degenerative changes characterized by cellular swelling, vacuoles in cytoplasm of renal tubular epithelial cells and occlusion of tubular lumen (Fig. 4). Similarly, the alveoli of fetal lungs exhibited air spaces with wavy outlines, bronchioles and single layer of capillaries (Fig. 5).



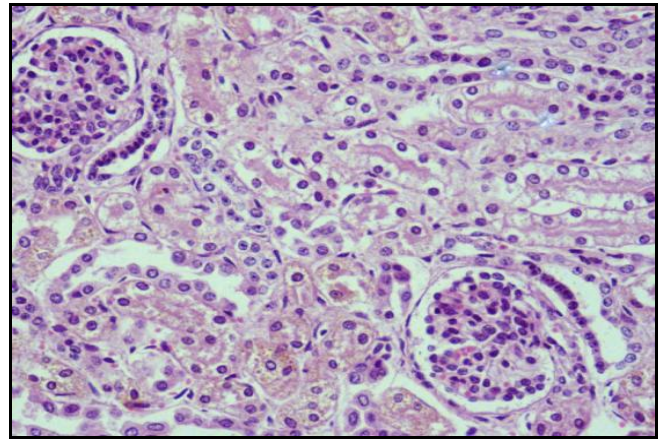
**Fig 1:** Dead fetus with lipomatous mass



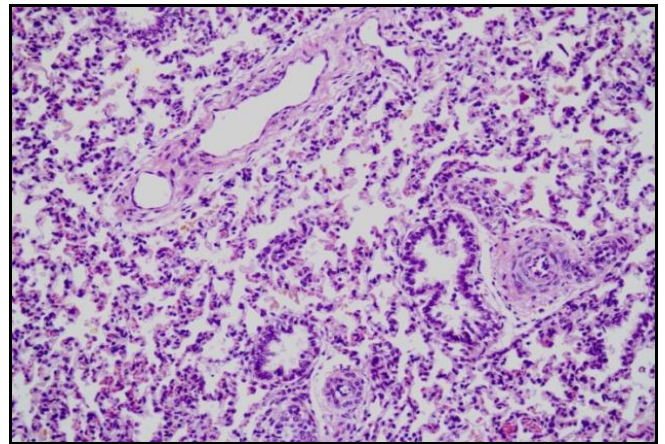
**Fig 2:** Section of lipomatous mass showing adipose cells with eccentrically placed nuclei. H&E×400



**Fig 3:** Section of liver showing vacuolar degenerative changes in hepatocytes and infiltration of mononuclear cells mainly lymphocytes (arrows) in periportal areas. H&E×400



**Fig 4:** Section of foetal kidney showing cellular degenerative changes characterized by cellular swelling, vacuoles in cytoplasm of renal tubular epithelial cells and occlusion of tubular lumen. H&E×400



**Fig 5:** Section of foetal lung showing developing alveoli exhibiting air spaces with wavy outlines, bronchioles and single layer of capillaries. H&E×100

### Discussions

Fetal ascites is seen as an occasional cause of dystocia in many species but occurs most often in the cow. It may be caused either by the overproduction or insufficient drainage of fetal peritoneal fluid. Obstruction of the lymphatics, for various reasons may prevent the disposal of peritoneal fluid [7]. Ascites can also occur due to reduced urinary excretion [8]. Lipomas are rare in cattle and usually are located in internal organs. Relieving the dystocia in lipomatosis calves in anterior presentation is difficult when compared to posterior presentation due to accumulation of fat in abdominal cavity. Sometimes the long pedunculated lipomas that may be found in the abdomen may twine around the intestines causing strangulation [9]. Cases of dystocia due to fetal ascites [10] and lipomas [11] in buffaloes have been reported.

### References

1. Albarella S, Ciotola F, D'Anza E, Coletta A, Zicarelli L, Peretti V. Congenital Malformations in River Buffalo (*Bubalus bubalis*) animals. 2017; 7(2):1-15. doi: [10.3390/ani7020009]
2. Noakes DE, Parkinson TJ, England GCW. Veterinary Reproduction and Obstetrics, 10<sup>th</sup> Edition, Elsevier Ltd. 2009, 192.
3. Ozmen O. Congenital lipomatosis in a Brown Swiss calf. Revue Med. Vet. 2005; 156(4):191-193.

4. Sickinger M, Erichsen JV, Koehler K, Doll K, Reinacher M. Congenital infiltrative lipomas in a calf. *Journal of Veterinary Diagnostic Investigation*. 2009; 21:19-721.
5. Yeraham IPS, Orgad U. Congenital skin neoplasia in cattle. *Veterinary Dermatology*. 1999; 10:149-156.
6. Kumar DD, Murali Krishna BV, Ramakrishna V. Dystocia due to foetal lipomatosis in a she buffalo. *Indian Vet. J.* 1997; 74:687-688.
7. Sloss V, Duffy JH. *Handbook of bovine obstetrics*. Williams and Wilkins, Baltimore, USA, 1980, 121
8. Purohit GN, Kumar P, Solanki K, Shekhar C, Yadav SP. Perspectives of fetal dystocia in cattle and buffalo. *Vet. Sci. Dev.* 2012; 2(8):31-42.
9. Sastry GA. *Text book of Veterinary pathology*. Chapter 13. Neoplasms. 7<sup>th</sup> Edition, 2006, 230.
10. Singh G, Dutt R, Yadav V, Patil S, Jain VK. Dystocia due to fetal ascites in Murrah buffalo: Study of two cases. *International Journal of Chemical Studies*. 2018; 6(5):2361-2362.
11. Singh G, Pandey AK, Dutt R, Sunder S, Kumar S, Kumar R. Delivery of a bull dog calf with lipomas in a buffalo. *Indian Veterinary Journal*. 2013; 90(1):91-92