



ISSN: 2456-2912  
VET 2018; 3(5): 113-115  
© 2018 VET  
www.veterinarypaper.com  
Received: 20-07-2018  
Accepted: 22-08-2018

**Gyan Singh**  
Department of Veterinary Clinical  
Complex, College of Veterinary  
Sciences, Lala Lajpat Rai  
University of Veterinary and  
Animal Sciences, Hisar, Haryana,  
India

**Ram Niwas**  
Department of Veterinary Surgery  
and Radiology, College of  
Veterinary Sciences, Lala Lajpat  
Rai University of Veterinary and  
Animal Sciences, Hisar, Haryana,  
India

**Ravi Dutt**  
Department of Veterinary  
Gynaecology and Obstetrics,  
College of Veterinary Sciences,  
Lala Lajpat Rai University of  
Veterinary and Animal Sciences,  
Hisar, Haryana, India

**S Patil**  
Department of Veterinary  
Gynaecology and Obstetrics,  
College of Veterinary Sciences,  
Lala Lajpat Rai University of  
Veterinary and Animal Sciences,  
Hisar, Haryana, India

**Karan Sharma**  
Department of Veterinary  
Gynaecology and Obstetrics,  
College of Veterinary Sciences,  
Lala Lajpat Rai University of  
Veterinary and Animal Sciences,  
Hisar, Haryana, India

**Vinay Yadav**  
Department of Veterinary  
Gynaecology and Obstetrics,  
College of Veterinary Sciences,  
Lala Lajpat Rai University of  
Veterinary and Animal Sciences,  
Hisar, Haryana, India

#### Correspondence

**Ravi Dutt**  
Department of Veterinary  
Gynaecology and Obstetrics,  
College of Veterinary Sciences,  
Lala Lajpat Rai University of  
Veterinary and Animal Sciences,  
Hisar, Haryana, India

## Prolapse of complete gravid genitalia in a pre-partum murrah buffalo and its surgical management: A rare case

**Gyan Singh, Ram Niwas, Ravi Dutt, S Patil, Karan Sharma and Vinay Yadav**

#### Abstract

A seven months pregnant Murrah buffalo heifer suffering from irreducible prolapse of complete gravid genitalia was brought to Veterinary Clinics of the university and emergency surgery was carried out to remove the gravid uterus along with cervix to save the life of the animal.

**Keywords:** Buffalo, gravid genitalia, prolapse, surgery

#### Introduction

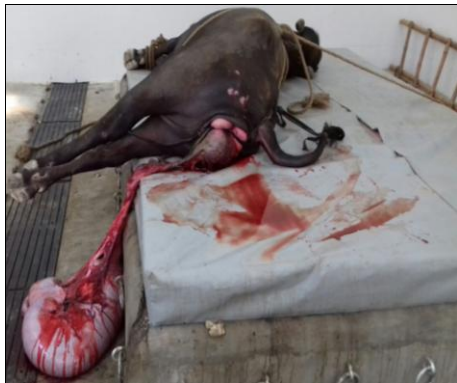Among reproductive disorders, prolapse of complete gravid genitalia is a rarest gestational accident in bovines. Uterine prolapse is the protrusion of the uterus from the vulva with the mucosal surface exposed [1]. It is most commonly seen in pluriparous dairy animals as compared to Primiparous [2]. The complete prolapse of gravid uterus is extremely serious condition in farm animals and has not been reported, so far. Pre-partum uterine prolapse is rare condition than post partum the prolapse [3]. However, post- partum uterine prolapse most commonly occurs immediately after parturition and occasionally up to several days afterwards. The relaxation of pelvic ligaments, along with straining, lack of uterine tonicity, increase in intra abdominal pressure, uterine inertia and loss of muscular tonicity might be the cause of uterine prolapse [4]. The forced extraction over relaxation of the pelvic structure, flaccid uterus and hyper-estrogenism are also considered as predisposing factors [5, 6]. Generally cervico-vaginal prolapse observed during 2<sup>nd</sup> and 3<sup>rd</sup> trimester of gestation period in bovines that is about 2<sup>nd</sup> degree, but very rarely, the prolapse of gravid uterine horn is seen during pre-partum period. The present clinical case study reports a very rare case of pre-partum complete uterine prolapse in a primiparous Murrah buffalo and its surgical management.

#### Case Report

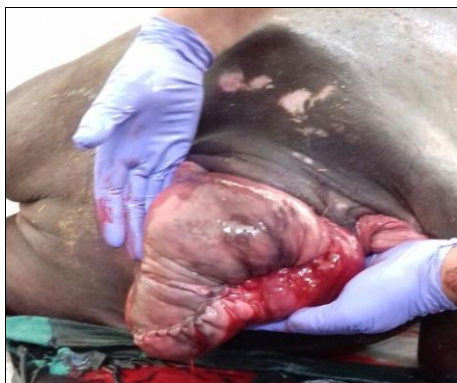A seven months pregnant buffalo heifer (OPD No. 6-12953 dated 22.06.2018) suffering from eversion of gravid uterus was brought to the Veterinary Clinical Complex of the university. Anamnesis revealed chronic and recurrent cervico-vaginal prolapse for the last one month. Since then, the rope truss was applied and herbal therapy was carried out. Around 6 hours back during cleaning of the perineum of the animal, the rope truss was loosened and sudden eversion of gravid horn had occurred. At the time of presentation of animal at the clinics, the eversed gravid uterus was held in a cloth and tied over the sacral region of the animal. Just at the opening of the cloth for examination, the uterus along with both the cornua and cervix fell down on the ground. Immediately, the epidural anaesthesia was given with 6 ml of 2% lignocaine between 1<sup>st</sup> and 2<sup>nd</sup> inter-coccygeal space. The bleeding was controlled by applying artery forceps over the bleeding points and prolapsed mass was cleaned with mild potassium permanganate solution. Hence, it was irreducible prolapse of gravid uterus through the vulva (Fig. 1).

Keeping the general health of the animal in mind an emergency surgery was planned to remove the gravid uterus along with cervix with the consent of owner.

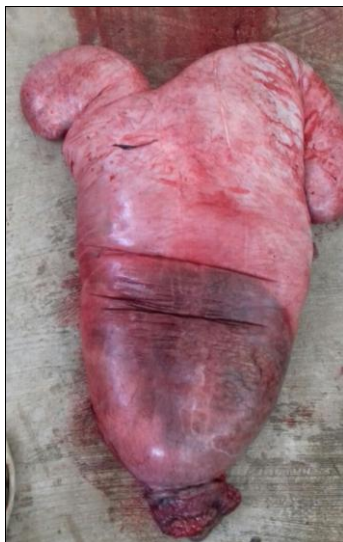The blood vessels were ligated, the gravid uterus was detached by using BP blade ligating the stumps and vaginal wall was sutured (Fig. 2 & 3) to avoid evisceration of abdominal contents through vulva. Both the ovaries were left intact. The urinary bladder was catheterized by using Foley's catheter no. 18 to prevent straining while micturition and modified Buhner's sutures were applied over the vulvar lips using infusion (drip) set tubing as suture material (Fig. 4). During the surgery, animal was administered with Inj. Normal saline 3 litres I.V., Inj. Metronidazole 2500 mg/500 ml I.V., Inj. Dexamethasone 40 mg I.V., Inj. Ceftriaxone 4 g I.V., Inj. Flunixin meglumine 1000 mg I.V., Inj. Tranexamic acid 2000 mg I.V. and Inj. Ascorbic Acid 7.5 g I.V. The animal was kept under observation and same treatment was continued for next 6 days. On seventh day, the Foley's catheter was removed and animal was discharged.



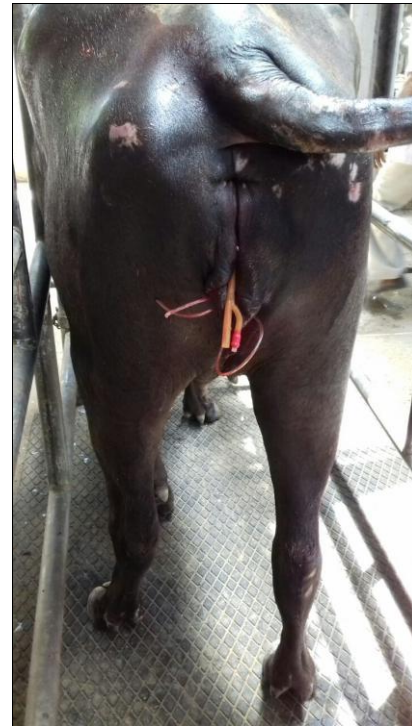
**Fig 1:** Prolapse of gravid genitalia in buffalo



**Fig 2:** Suturing of vaginal wall



**Fig 3:** Surgical removal of gravid uterus



**Fig 4:** Catheterization of urinary bladder and application of modified Buhner's sutures

### Discussions

Prolapsed gravid uterus is highly prone to mechanical injury, trauma, haemorrhage, necrosis, urinary incontinence, stress, shock and environmental contamination that lead to increased maternal morbidity and even though sometime death of the animal [7]. It is a serious problem for the buffalo breeding on national and international level where it constitutes 11% for culling, from main herd of primiparous buffaloes [9] which is a big economic loss. In the present case, the uterus along with cervix was surgically removed and future fertility was sacrificed. This was a unique case of complete genital prolapse and no such case is reported before.

### Conclusions

The due attention must be paid at initial stages of the cervico-vaginal prolapse. Otherwise, the chronic and recurrent pre-partum cervico-vaginal prolapse turns into irreducible one. Therefore, the genital prolapse is regarded as an emergency condition and should be managed before excessive edema, mucosal trauma, contamination, fatal haemorrhage, shock and complete prolapse of genitalia.

### References

1. Gustafsson H, Kornmatitsuk B, Koningsson K, Kindahl H. Peripartum and early post-partum in the cow - physiology and pathology. Proceeding of 23<sup>rd</sup> Congress mondial de buiatrie. Quebec, Canada, 2004, 11-16.
2. Joseph C, Kulasekar K, Balasubramanian S, Kathiresan D, Veerapandian C, Pattabiraman SR. An unusual complication of post-partum uterine prolapse in a she buffalo-a case report. Indian Vet. J. 2001; 78:57-58.
3. Roberts SJ. Veterinary Obstetrics and Genital Disease (Theriogenology), 2<sup>nd</sup> ed. CBS Publishers and Distributors, New Delhi, India, 1971, 189-196.
4. Arthur GH, Noakes DE, Pearson H. In: Veterinary Reproduction and Obstetrics (Theriogenology), 6<sup>th</sup> ed. Bailliere and Tindal, London, UK, 1996, 302-307.

5. Hanie EA. Prolapse of the vagina and uterus: Textbook of Large Animal Clinical Procedures for Veterinary Technicians. Elsevier, Mosby, 2006.
6. Jackson PGG. Postparturient Problems in Large Animals. Handbook of Veterinary Obstetrics, 2<sup>nd</sup> ed., Elsevier Saunders, 2004.
7. Jana D, Ghosh M. Management of prepartum cervical prolapse in indigenous she buffalo-A case report. *Intas Polivet*. 2004; 5:147-148.
8. Peeva Tz, Ilieva Y. Longevity of buffalo cows and reasons for their culling. *Italian J Anim. Sci*. 2007; 6(2):378-380.