International Journal of Veterinary Sciences and Animal Husbandry

**ISSN:** 2456-2912
VET 2017; 2(4): 04-09

www.veterinarypaper.com
Received: 05-05-2017
Accepted: 06-06-2017

**Ilayaraja Selvaraj**
Deputy Director veterinary services, Wildlife SOS, New Delhi, Delhi, India.

**Arun A Sha**
Director Veterinary research, Wildlife SOS, New Delhi, Delhi, India

**Puspendra K Singh**
Junior veterinary Officer, Wildlife SOS, New Delhi, Delhi, India

**Correspondence**
**Arun A Sha**
Director Veterinary research, Wildlife SOS, New Delhi, Delhi, India

# Echocardiography in sloth bear (*Melursus ursinus*) - A preliminary approach

**Ilayaraja Selvaraj, Arun A Sha and Puspendra K Singh**

**Abstract**
Echocardiography is the accepted term for the study of cardiac ultrasound. It is a technique by which we can do the imaging of the heart with the help of ultrasonography machine with a suitable probe. These techniques provide valuable diagnostic information without risk to the patient as it is a non-invasive procedure. The M-mode, two-dimensional (2D mode), and Doppler mode are maximum practiced techniques in echocardiography. Since there is no need of anaesthesia and special restraining procedure, the echocardiography is well developed and has become an integral part of cardiac evaluation of humans, small animal practices and reptile medicine especially in ophidian as well. But due to the huge body size and need of special restraining procedure with anaesthesia this technique is not established enough in wildlife practice particularly in sloth bear that belongs to ursidae family. The objective of this study is to develop the procedure for assessment of optimal approaches of echocardiography in sloth bears such as instrument selection, patient preparation and positioning etc and establish a cardiac image catalogue. This will help to identify the normal echo-anatomy of the heart and possible measurements B mode and M mode for further evaluation of the normal echocardial anatomy and colour flow Doppler to understand the normal blood inflow and outflow of heart.

**Keywords:** Echocardiography, Heart, Sloth bear, B-mode, M-mode, Doppler mode, Ultrasonography

## 1. Introduction

The use of ultrasound in veterinary medicine is widespread as a diagnostic supplement in the clinical routine of small animals, but there are few reports in wild animals [6, 12]. It is a non-invasive approach for exploration of morphology, topographic anatomy, and biological process in Non-domestic animals [13]. This imaging technique is still underutilised in wildlife medicine due to the limited knowledge of the topography and ultrasound anatomy of their organs and also the need for anaesthesia with special restraining procedure [12]. According to individual anatomical structure in different vertebrate taxa; use of ultrasonography is combined with the characteristic feature for applying this imaging technique [13]. Advanced progress of imaging modality in veterinary sciences is being improved in ultrasound technology through the development of new types of probes for different applications such as cardiovascular, abdominal and intra cavity ultrasonography scanning. Echocardiography is the accepted term for the study of cardiac ultrasound. Echocardiography uses sound waves in the order of frequency of greater than 20000 Hz. Piezoelectric crystals, in the form of a transducer, emit ultrasonic waves at high frequency when subjected to an alternating current. This same transducer receives the reflected waves and forwards them to be electronically processed and displayed for interpretation via one of three modes such as B-mode, M-mode and Doppler mode [3]. Echocardiography is a safe [1, 8], non-invasive method that provides quantitative information of cardiac wall thicknesses, internal cavity dimensions, valve motion, ventricular function and the presence or absence of intra cardiac structures [4, 5, 7]. The objective of this study is to develop the procedure for assessment of optimal approaches of echocardiography in sloth bears and establish a cardiac image catalogue for further feature study reference. Since the Agra bear rescue facility is a life time care and rehabilitation centre for the rescued dancing sloth bears which have come from poor health background [10], the initial and periodic health screening by adopting recent technique is more necessary to keep them in a comfortable healthy status and to establish preventive health care protocols.

## 2. Materials and method

Since ultrasound propagates poorly through gaseous or bony media, an area free of lung interface must therefore be determined to achieve a proper cardiac imaging. Proper patient preparation and positioning, examination table selection, selection of suitable ultrasonography machine with required probe/transducer and knowledge of the sonographer regarding the different modes of ultrasonography along with basic organ anatomy and its topography within the body cavity (Fig.1) of the animal patient are major factors which influence the efficient echocardiographic examination in the desired animals.

### 2.1 Patient preparation and positioning

For getting good cardiac image the patient needs to be stationary in position and the transducer needs to be in contact with the animal's skin as close as it can be without air pockets in between the transducer and skin. This can be achieved by chemical immobilization of the bear and clip or shave the hair on the intercostal region where we can recognise the apical beat then clean thoroughly eliminate the skin debris and dirt if any otherwise it may cause poor image quality by causing hindrance to the ultrasound beam penetration.

The bear was tranquilized as per the standard protocol with Injection Xylazine @ 2 mg/kg and Injection Ketamine @ 5 mg/kg intramuscularly using blow pipe [11]. Both left and right side hemithorax region clipped and cleaned thoroughly and the coupling gel is applied on the scanning area 5 minutes prior to start the examination to allow the gel to soak the skin tissue and avoid air pockets. This will enhance the penetration of ultrasound beam and produce good quality image. The bear was kept in right lateral recumbency and the right forelimb gently pulled and kept cranially (Fig.2). The same was followed for left forelimb while positioning the bear in left lateral recumbency.

### 2.2 Equipment selection

Sloth bears have body weights ranging between of 60 – 120kg. The patient's examination table needs to be selected accordingly to bear's weight without compromising and also it should possess the facility to reach the animal's hemithorax region with the scanning probe without any difficulties to the operator and bending the probe cable as well. We specially designed the examination table for this procedure in such a way to full fill the above said requirements (Fig.3). Any ultrasound machine with cardiac package and Transducer with small foot print can be used for Echochocardiographic studies as like in medical and small animal veterinary practices. We used LOGIQ *e* manufactured by GE healthcare company and Phased array transducer (model 3S-RS).

### 2.3 Organ anatomy

As like other mammalian species sloth bears also possess the well-developed 4 chambered heart with valves in the mediastinal cavity. The cardio vascular system has resemblance as close as to humans and canines, so we followed the echo cardiographic studies as described by the previous authors in mammalian species especially in dogs. We performed right parasternal long (Fig. 4) and short axis (Fig. 5), left apical parasternal location (Fig 6) views along with M mode (Fig.7) and Doppler mode (Fig.8 & 9) recorded the images [14].

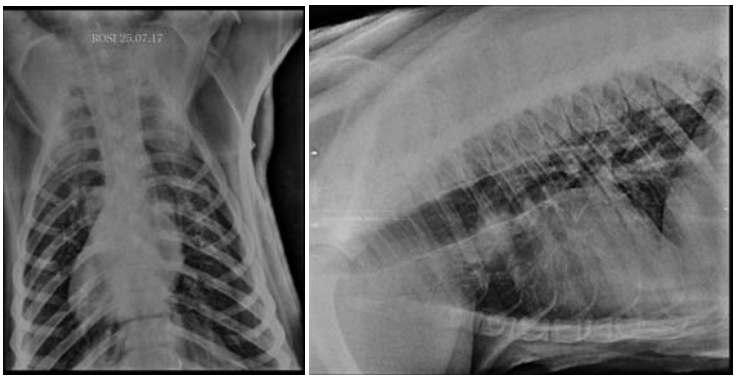

**Fig 1:** Radiograph showing location of heart inside the thoracic cavity of a normal sloth bear.

**Fig 2:** The bear kept in right lateral recumbency and the right forelimb gently pulled and kept cranially on the examination table after clipped the hair

**Fig 3:** Echocardiography examination table model.

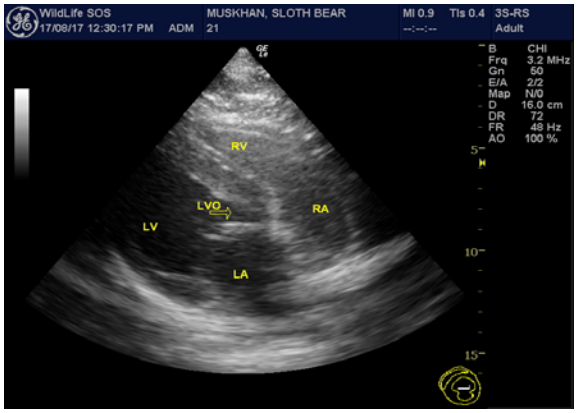


**Fig 4:** Right parasternal long axis view

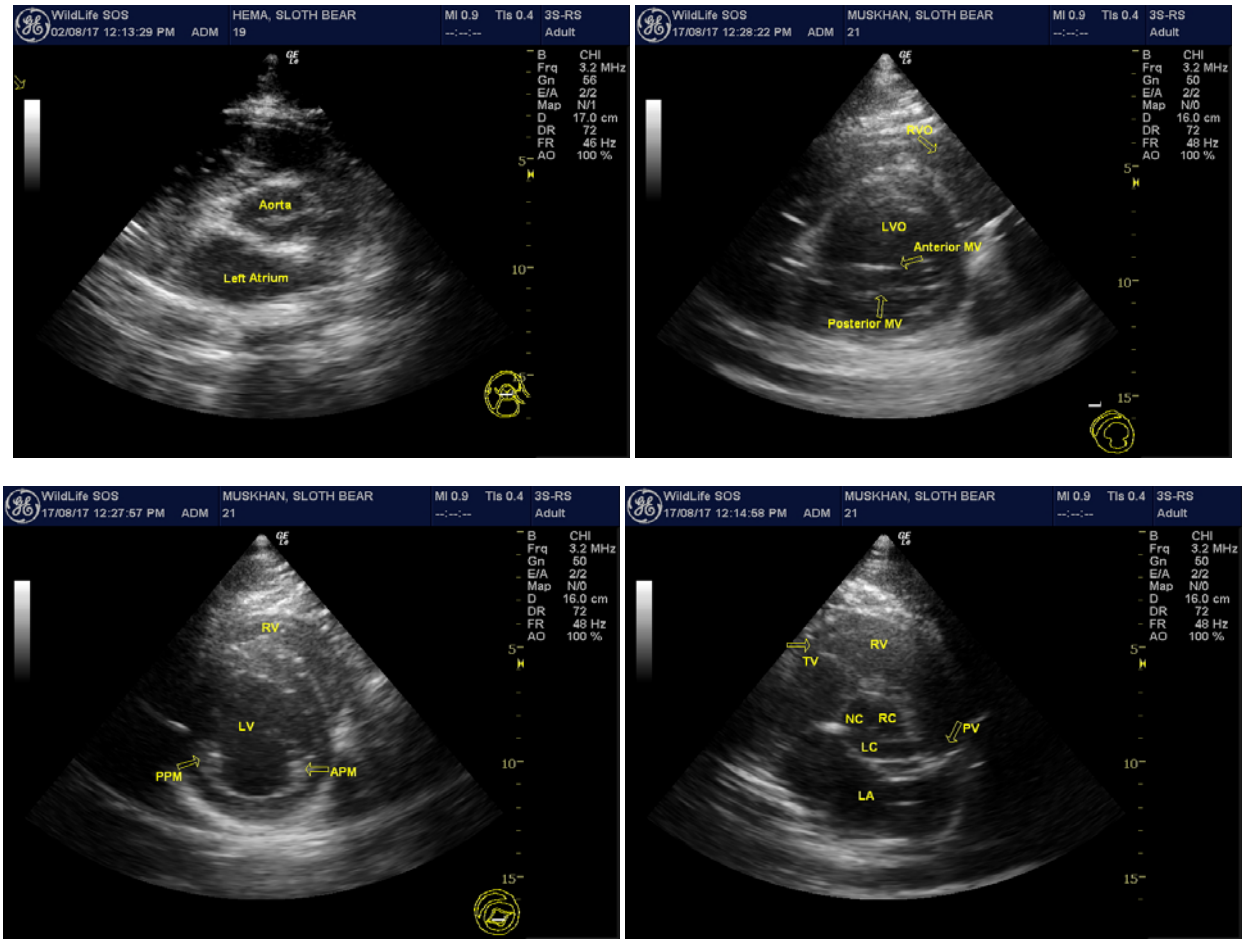


**Fig 5:** Right parasternal short axis views

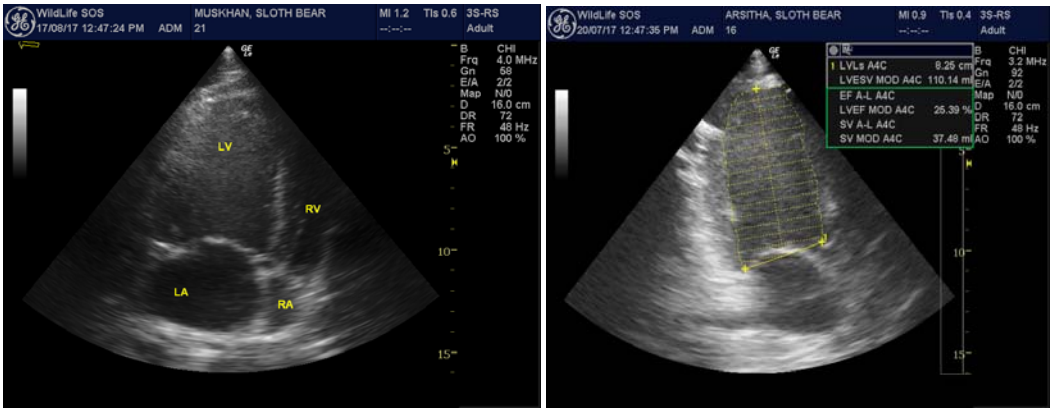


**Fig 6:** Left parasternal apical four & two chamber view

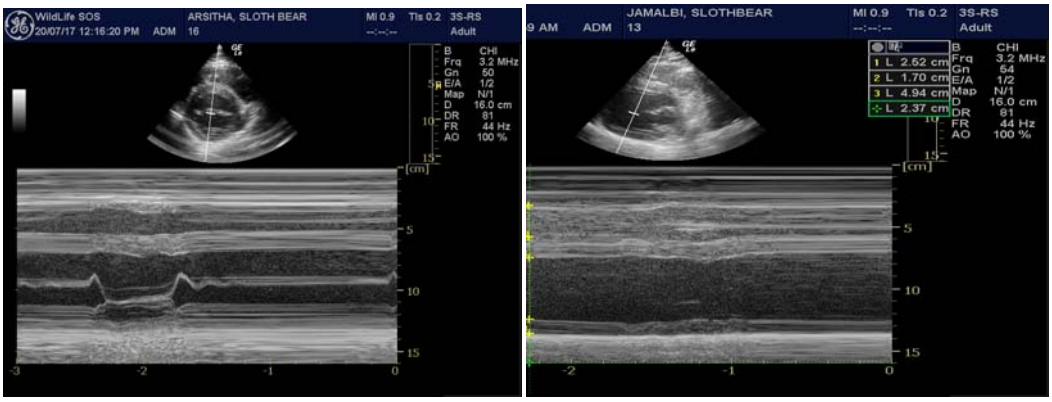


**Fig 7:** M mode view for mitral valve activity & left ventricle

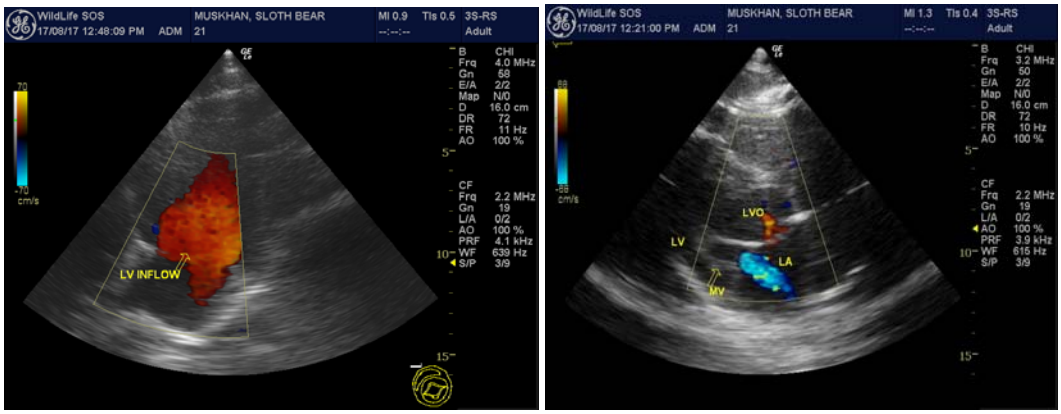


**Fig 8:** Colour Doppler mode showing left ventricle blood flow

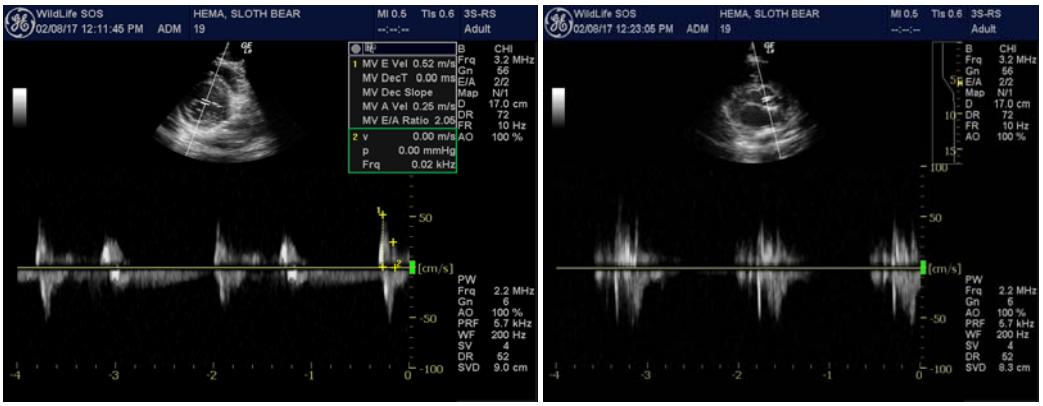


**Fig 9:** Pulsed wave Doppler- Mitral valve and Aortic valve activity

### 2.4 Types of echo Display Modes

There are three basic modes to consider in Echocardiography for complete evaluation of heart anatomy and its functions effectively.

B-mode or brightness is the electronic conversion of the A-mode and A-line information into brightness-modulated dots on a display screen. The brightness of the dot is proportional to the echo signal amplitude [9]. The B-mode display is used for M-mode and 2D gray-scale imaging. This gives good cross-sectional images of the heart and is useful to identify conditions such as pericardial effusion, chamber enlargement and valvular disease.

M-mode (M for motion) is a technique that uses B-mode information to display the echoes from a moving organ, such as the myocardium and valve leaflets, from a fixed transducer position and beam direction on the patient. The echo data from a single ultrasound beam passing through moving anatomy is acquired and displayed as a function of time, represented by reflector depth on the vertical axis (beam path direction) and time on the horizontal axis. Since M-mode can provide excellent temporal resolution of motion patterns, it is used to evaluate chamber size and contractility, as well as indices of cardiac function.

Doppler mode consists of four types of Doppler ultrasound, which rely on the change in frequency of returning echoes depending on whether flow is towards or away from the transducer. Pulsed wave Doppler (PWD) – 'gates' identifies the specific sampling area e.g. across the mitral valve. Unfortunately PW cannot calculate high velocities due to a phenomenon called 'aliasing'. Continuous wave Doppler (CWD) – can identify high velocity but the exact location of the flow cannot be identified. Colour flow Doppler (CFD) – provides an easy visual identification of flow direction and velocity by producing red and blue coloration [9]. It can be remembered as BART= blue away red towards. Colour Doppler is angle dependent so that no Doppler shift is recorded when blood flow is 90 degrees to the transducer. The combination of all three types of Doppler is used in practice as per the need or as a routine examination procedure. Power Doppler (PD) detects very-low-velocity blood flow and small blood vessels. It is not prone to 'aliasing' artifact as it is essentially angle independent [2, 9].

## 3. Result and Discussion

The right parasternal long axis is the best view for visualising left ventricle (LV) apex, mitral valve (MV), LV out flow tract (LV O), aortic valve (AV), proximal ascending aorta, left atrium and interventricular septum. The right parasternal short axis is the suitable view for LV apex, high papillary muscle level, chordae tendineae of the LV, mitral valve (MV), aortic valve, pulmonary arteries and pulmonic valve. Left parasternal apical long axis will help us to see the LV, MV, and left atrium (LA), with slight anticlockwise rotation the LV O can be seen. Left cranial parasternal location, short axis view at the level of the aortic root provides the right ventricular inflow and outflow tracts clearly. However we followed the previous author's recommendation, we did necessary fine adjustments of transducer position and angulation and image plane orientation in sloth bears to obtain optimal cardiac images. Since the transducer movement and angulation is too sensitive we can't achieve proper echocardiography in sloth bear without sedation. This image modality would be helpful to carryout efficient diagnosis of the cardiac problems such as pericardial effusion, dilated cardiomyopathy and degenerative valve disease efficiently in sloth bears.

## 4. Conclusion

Since echocardiography is a non-invasive and risk free technique and provides a wealth of data concerning cardiac morphology and function, it has to be an integral part of health examination in sloth bears and other captive wild animals as well. Adaptation of this procedure and images should facilitate consistent performance and provide basic information for further studies in future. It should always be borne in mind that echocardiography is a specialist area, requiring a thorough knowledge of cardiac anatomy and pathophysiology. Referral to a cardiologist should be considered if it is an option, and is a useful way of learning.

## 5. Acknowledgement:

We are sincerely thanking to BCF Technology and Dr. Nicolette Hayward for the generous donation of cardiac probe. We appreciate the great active effort of Ms. Tracianna Morrell Myers., Australia for the donation of Ultra-sonography machine. We are grateful to Mr. Kartick Satyanarayan & Geeta Sheshmani Co-Founders, Wildlife SOS for their tire less support and all our animal care staff of wildlife SOS, India.

## 6. Reference

1. Baker ML, GV. Dalrymple. Biological effects of diagnostic ultrasound. A Review. *Radiology.* 1978; 126:479-483.
2. Boote EJ. AAPM/RSNA physics tutorial for residents: topics in US: Doppler US techniques: concepts of blood flow detection and flow dynamics, *Radiographics.* 2003; 23:1315.
3. Allen DG. Echocardiography as a Research and Clinical Tool in Veterinary Medicine, Can. Vet. J. 19822; 3:313-316.
4. Feigenbaum H. Echocardiography 2nd Edition. Philadelphia: Lea & Febiger, 1976, 1-340.
5. Fortuin NJ, Hood WP, Craige E. Evaluation of left ventricular function by echocardiography. Circulation, 1972; 46:26-35.
6. Göritz F, Hildebrandt T, Jewgenow K, Wagner N, Hermes R, Strauss G *et al*. Transrectal ultrasonographic examination of the female urogenital tract in nonpregnant and pregnant captive bears (Ursidae). J Reprod Fertil Suppl. 1997; 51:303-12
7. Gutgesell HP, Paquet M, Duff DF, McNamar DG. Evaluation of left ventricular size ad function by echocardiography. Results in normal children. Circulation. 1977; 56:457-462.
8. Kirk. Bistner's. Hand book of Veterinary Procedures and Emergency Treatment; 7th Edition. W.B. Saunders company, Philadelphia. 1995, 311-313.
9. Kremkau FW. sonography:principles and instruments, ed 8, St.Louis,Elsevier Saunders. 2011; 13(69):127-176.
10. Milella L. Dental disease in rescued dancing bears. Companion Animal, 2007; 12:75-79.
11. Page CD. Sloth bear immobilization with ketamine-xylazine combination: Reversal with yohimbine. Journal of the American Veterinary Medical Association. 1986; 189:1050-1051.
12. Rejane Ribeiro G, Ana Paula Costa A, Nathália Bragato, Angela Fonseca M, Juan Duque CM. Tales D Prado, Andrea CR Silva and Naida C Borges. Normal

sonographic anatomy of the abdomen of coatis (Nasua nasua Linnaeus 1766). BMC Veterinary Research, 2013; 9:124.

13. Thomas Hildebrandt B, Frank Göritz, Robert Hermes, Fritsch Guido. Ultrasonographic Techniques Applied to Non-Domestic Species. *Ultrasound*. 2002; 10(2):7-14.
14. Thomas WP, Gaber CE, Jacobs GJ, Kaplan PM, Lombard CW, Moise NS *et al*. Recommendation for standards in transthoracic two- dimensional echocardiography in the dog and cat. J. Vet. Intern. Med., 1993; 7:247-252.